



CRACKCast E168 – Pediatric Respiratory Emergencies: Upper Airway Obstruction and Infections

Key concepts

Respiratory arrest precedes most pediatric cardiac arrests. You better recognize any airway problem ASAP!

Retropharyngeal Abscess

- This is a potentially life-threatening emergency in young children with signs of upper airway obstruction or meningismus; a retropharyngeal abscess is often related to oral trauma.
- Retropharyngeal abscess is most frequently caused by *Staphylococcus aureus*, group A streptococci, and anaerobes. Treatment is admission, IV antibiotics and, for more severe cases, surgical drainage.

Epiglottitis

- Epiglottitis may be caused by many bacteria or local injury. In the post-H. influenzae type b vaccine era, the typical profile of epiglottitis has changed to include older patients.
- Clinical features of epiglottitis are often subtle, such as in the older adolescent, (eg, sore throat out of proportion to physical findings, anterior neck tenderness), but may also be dramatic, as in infants and young children (ie, drooling, stridor, toxicity, severe respiratory distress).

Croup

- Viral croup is the most common infection of the upper airway in young children.
- Glucocorticoids (single oral dose of dexamethasone) reduces symptoms, hospitalizations, and length of stay in the ED. (it doesn't get rid of the croupy cough!)
- Treatment of moderate to severe croup includes vaporized epinephrine in addition to glucocorticoids. These patients can be discharged from the ED after a posttreatment observation period of 2 to 3 hours if they remain free of stridor and distress and have access to follow-up care.

Bacterial Tracheitis

- Suspect bacterial tracheitis when a URI progresses to acute toxicity and marked respiratory distress and stridor. Standard treatment for croup should be initiated but does not improve the patient's symptoms. Antibiotic therapy should include a cephalosporin plus coverage for *S. aureus*, which is the most common cause of this infection.
- Bronchoscopy is diagnostic and therapeutic and should be emergently performed.

Airway Foreign Body

- Complete obstruction due to an airway foreign body requires emergent basic followed by advanced life support procedures for removal of the foreign body.
- Plain films may be negative in aspirated foreign bodies. Bronchoscopy should be performed with a clinical suspicion of



aspiration.

- Emergency cricothyroidotomy may be required for obstructed patients who cannot be intubated or ventilated as a lifesaving temporizing measure; needle cricothyroidotomy is preferred for infants and young children because of the challenges in identifying landmarks and associated complications of surgical cricothyrotomy.

Core questions:

1. What is the pathophysiology of inspiratory and expiratory stridor?
2. Provide a differential diagnosis for stridor in children (based on location: supraglottic, glottic, subglottic) list at least three in each category.
3. What is the typical presentation of a retropharyngeal abscess?
4. Describe the management of a RPA. What are the typical pathogens?
5. What the typical pathogens in epiglottitis? How are these patients managed?
6. Differentiate between croup and other conditions mimicking croup.
7. Contrast mild, moderate, and severe croup.
8. What is the management of croup?
9. Which children with croup require admission to hospital?
10. Management of upper airway FB: Describe the management of an airway obstruction (progresses from partial obstruction to full obstruction to unconscious) in a 6 month old. In a 6 year old?

Wisecracks:

1. Ddx of stridor (8) (review)
2. List 5 Xray findings of epiglottitis
3. Which infections are associated with croup?
4. How do you handle the CICV scenario?

Rosen's In Perspective

- Big categories for upper airway obstruction:
 - Infectious, congenital, foreign body (IN THE AIRWAY OR ESOPHAGUS!)
 - Congenital causes:
 - Think of progressive stridor or feeding difficulties.
- In addition to the onset and duration of symptoms, ask about:
 - DROOLING
 - NECK STIFFNESS/TORTICOLLIS
 - EXACERBATING FACTORS
 - CHOKING EPISODES
- Try to think out loud with the team:
 - Is this resp distress or resp failure?
 - *Respiratory failure is identified by the presence of extreme distress, hypoventilation or hyperventilation, altered mental status, pale, mottled or cyanotic skin color, and/or hypotonia.*
 - ****stridor can be absent****
- You should know the normal structures on a lateral soft tissue neck xray:

See Figure 167.3 in the text.



Core questions:

[1] What is the pathophysiology of inspiratory and expiratory stridor?

Stridor (from the Latin, stridulus, indicating creaking, whistling, or grating) is the classic sound associated with upper airway obstruction.

Stridor is a harsh vibratory sound of variable pitch caused by partial airway obstruction or collapse and the resultant turbulent airflow through some portion of the airway, from the nose to the trachea. Stridor is described by timing in the respiratory cycle (inspiratory, expiratory, biphasic) and quality (coarse or high-pitched).

**Inspiratory = pathology above the glottis
 Biphasic = pathology at the glottis
 Expiratory = pathology below the glottis
 I before E.**

(see figure 167.2 in Rosens)

What about stertor/snoring?

Snoring or stertor is low-pitched inspiratory noise caused by nasal or nasopharyngeal obstruction. Stertor and stridor can coexist. Stridor from the pharynx, such as from a peritonsillar abscess, tends to have a sonorous, gurgling, and coarse quality. The voice may be altered and have a muffled or “hot potato” quality to it. High-pitched inspiratory stridor occurs in the supraglottic and immediate subglottic trachea, as in croup and laryngomalacia.

[2] Provide a differential diagnosis for stridor in children (based on location: supraglottic, glottic, subglottic) list at least three in each category.

	supraglottic	glottic	Subglottic
sound	Inspiratory snoring/stertor/gurgling (low-pitched)	Biphasic	Expiratory
Congenital	Craniofacial Pierre Robin Treacher-Collins Hallermann-Streiff • Macroglossia	Laryngomalacia • Vocal cord paralysis • Congenital subglottic stenosis	Tracheomalacia • Tracheal stenosis • Vascular rings, slings • Mediastinal



	Beckwith-Wiedemann Down syndrome Glycogen storage disease Congenital hypothyroidism • Choanal atresia • Encephalocele • Thyroglossal duct cyst • Lingual thyroid	• Laryngeal web • Laryngeal cyst • Subglottic hemangioma • Laryngotracheoesophageal cleft	masses
Acquired	Epiglottitis Pharyngeal abscess Adenopathy Tonsillar hypertrophy Foreign body	Foreign body Papillomas / hemangiomas of the vocal cord Paradoxical vocal cord dysfunction.	Subglottic stenosis Bacterial tracheitis Croup Foreign body

See Figure 167.1 in the text.

[3] What is the typical presentation of a retropharyngeal abscess?

The retropharyngeal space is a **potential space between the posterior pharyngeal wall and prevertebral fascia that extends from the base of the skull to the level of T2**. It is rich in lymph tissue that drains the nose, pharynx, sinuses, and ears.

An abscess may result from:

- direct trauma from a fall with an object in the mouth such as a toothbrush,
- suppurative of lymph nodes,
- contiguous spread of infection,
- hematogenous seeding.

It is usually a disease of infants and toddlers because the lymphatic chains are prominent in the young and atrophy before puberty.

Approximately 50% of pediatric cases occur in children 6 to 12 months of age, most occur before 3 years of age, and 96% of all diagnosed pediatric retropharyngeal abscesses are seen before 6 years of age.

Clinical presentation:

- Fever
- Sore throat
- Neck stiffness or nuchal rigidity
- Torticollis
- Tismus
- Neck swelling
- Drooling



- Stridor, and muffled voice.

****look for the child who has reluctance to extend their neck or look side to side****

Xray- must be done with the child's head in EXTENSION (exactly what they want to avoid) and on INSPIRATION.

The soft tissue width should not be larger than 6 to 7 mm at C2, regardless of the patient's age. At C6, this distance should not exceed 14 mm in children younger than 15 years and 22 mm in adults.

See Figure 167.4.

A CT may help confirm the dx - but the child may NOT be able to lie flat. Airway takes precedence!

[4] Describe the management of a RPA. What are the typical pathogens?

Management depends on:

- The size of the abscess with resultant:
 - Clinical distress/toxicity of the patient
 - Degree of airway obstruction

Get help from an experienced ENT;

- These are difficult airways - may be distorted and at risk for rupturing!

Features that suggest abscess and require surgical intervention include:

- *imaging findings of scalloping of the abscess wall,*
- *rim enhancement,*
- *and lesions larger than 2 cm.*

The decision to admit and provide a trial of antibiotic therapy should be made between the emergency clinician and otolaryngology consultant.

Clindamycin and a third-generation cephalosporin are recommended antibiotic therapy.

Pathogens:

polymicrobial, with Streptococcus and anaerobes the most commonly isolated organisms.

Consider methicillin-resistant Staphylococcus aureus (MRSA) in severe infections such as jugular venous thrombosis or mediastinal extension.

[5] What the typical pathogens in epiglottitis? How are these patients managed?

Epiglottitis is an invasive bacterial disease that causes inflammation and edema of the epiglottis, aryepiglottic folds, arytenoids, and surrounding supraglottic tissues. As these structures become inflamed and distended, they protrude downward and over the



glottic opening. Supraglottic swelling reduces the upper airway caliber and causes turbulent airflow during inspiration (stridor).

The epiglottis may also act as a ball valve, obstructing GLOTTIC airflow during inspiration but permitting exhalation.

The traditional profile of Haemophilus influenzae type b (Hib) in young children has changed; the overall incidence has decreased, and now epiglottitis is relatively more common in older children and adults.

However, Hib is still the most common infectious cause of epiglottitis in children and can occur in fully immunized children.

Additional causes include other H. influenzae types (A, F, nontypeable), streptococci, and Staphylococcus aureus (including methicillin-resistant strains).

Immunocompromised children may have other infections such as Pseudomonas aeruginosa and Candida spp.

Noninfectious causes are rare and include thermal injury from swallowing of hot liquids, steam inhalation, caustic ingestions, allergic reactions, foreign body and irritant injuries, and lymphoproliferative disorders.

Let's recap:

- Haemophilus influenza B, A, F, nontypeable)
- Strep
- Staph.
- Pseudomonas
- Candida
- Non-infectious causes - thermal burns, chemical burns, allergic rxn, foreign bodies,

“Epiglottitis is classically acute in onset. It is marked by high fever, intense sore throat, toxicity, and rapid progression. Children with epiglottitis appear anxious and maintain a sniffing or tripod position, with the jaw jutting forward and the neck extended to maximize airway patency. As symptoms worsen, cough and phonation are usually absent. Drooling is prominent because of an inability to swallow. Toxicity, altered mental status, dyspnea, stridor, retractions, and fever are common initial symptoms; the diagnosis is often delayed and is associated with a significantly increased mortality rate.”

Management:

- **Stable patient:**
 - *Infants and children: A stable patient who is maintaining a patent airway and adequate oxygenation should **not be moved or repositioned for examination, laboratory tests, or radiography**. Such patients should be carefully transported to a setting where definitive airway management can be achieved in a controlled fashion, generally **the operating room**.*
 - **Adolescents and adults = have more real estate and rarely require airway management. They should be observed in the ICU and given IV abx.**
- **Unstable patient (respiratory failure):**
 - **Get help! (anesthesia, ENT, gensx)**
 - **Start with BVM and prepare for intubation**



- **Have a backup plan - needle ventilation / cut to air**

Patients often remain intubated for 3 to 5 days in order for antibiotic therapy to reduce inflammation and surrounding tissue edema. A second- or third-generation cephalosporin is recommended.

[6] Differentiate between croup and other conditions mimicking croup.

Croup (laryngotracheobronchitis) is the most common infectious cause of upper airway distress and obstruction in childhood.

It accounts for more than 90% of all cases of stridor in children. It usually occurs between 6 and 36 months of age but can be seen from early infancy through school age.

Parainfluenza virus accounts for 50% to 75% of cases; respiratory syncytial virus, influenza A and B viruses, and rhinovirus cause the remainder.

Croup is caused by inflammation, exudates, and edema of the loosely adherent mucosal and submucosal tissues of the subglottic space. The inflamed mucosa expands into the airway lumen because the cricoid cartilage forms a complete cartilaginous (non-expanding) ring in this part of the trachea.

“Croup is diagnosed clinically. A 1- to 3-day prodrome of mild fever and URI symptoms is followed by a fairly abrupt onset of barking cough, hoarse voice, and high-pitched inspiratory stridor. Croup symptoms typically resolve in 4 to 7 days.”

Now that you know what croup is, let's talk through things that can mimic it!

- **Foreign body aspiration**
- **Bacterial tracheitis**
- **Epiglottitis**
- **Retropharyngeal abscess.**

See Figure 167.10.



TABLE 167.2 (9th Ed.) Comparison of Croup, Epiglottitis, and Bacterial Tracheitis

PARAMETER	CROUP	EPIGLOTTITIS	BACTERIAL TRACHEITIS
Peak age	6 mo–3 yr	5–7 yr, but can be seen throughout childhood	3–5 yr, but seen throughout childhood
Pathologic features	Subglottic inflammation, edema	Inflammation and edema of the epiglottis, aryepiglottic folds	Bacterial superinfection with inflammation of the tracheal mucosa, copious mucopurulent secretions obstructing the trachea
Organisms	Parainfluenza virus, RSV, adenovirus, influenza	<i>Haemophilus influenzae</i> , group A beta-hemolytic streptococcus, <i>Staphylococcus aureus</i> , <i>Streptococcus pneumoniae</i>	<i>S. aureus</i> or mixed flora
Clinical features	Onset follows URI prodrome consisting of croupy cough, hoarse voice, low-grade fever, inspiratory stridor	Rapid progression of high fever, toxicity, drooling, stridor	Several-day prodrome of croup-like illness progressing to toxicity, inspiratory and expiratory stridor, marked distress
Laboratory and radiographic findings	Steeple sign on PA view of the neck or normal findings	Thumbprint sign on lateral aspect of the neck, thickened aryepiglottic folds, loss of air in the vallecula	Normal upper airway structures, shaggy tracheal air column
Management	Steroids uncommon, aerosolized epinephrine	Intubation, antibiotics	Intubation common, antibiotics rare, intubation

Notes on a few common congenital diseases:

- **Laryngomalacia** is the most common cause of chronic stridor in infants and accounts for 60% to 75% of congenital laryngeal anomalies. It is a result of incomplete development of the supporting cartilage of the larynx. With inspiration, the long floppy epiglottis, arytenoids, and aryepiglottic folds are drawn into the larynx and create a partial obstruction
- **Vocal cord paralysis** is the second most common cause of chronic stridor in infants.
 - **Bilateral = needs intervention**



- **Unilateral = usually left-sided and related to traction on the left recurrent laryngeal nerve at birth or compression from mediastinal structures. Infants with unilateral vocal cord paralysis have a hoarse weak cry, feeding difficulties, and aspiration.**
 - **Laryngeal webs**
 - **Subglottic stenosis (congenital or acquired)**
 - **Subglottic hemangiomas (look for the hemangiomas on the face) - usually peaks at 6 months**
 - **Acquired papillomas**

[7] Contrast mild, moderate, and severe croup.

Think about the patient: rest state, tachypnea, retractions, mental status changes

See Figure 167.10

Mild Croup

- **Stridor at rest or only when agitated**
- **No tachypnea**
- **No retractions**
- **No Mental Status Changes**

Moderate Croup

- **Stridor at rest**
- **Mild tachypnea**
- **Mild retractions**
- **No mental status changes**

Severe Croup

- **Stridor at rest**
- **Respiratory distress**
- **Severe retractions**
- **± Mental status changes present**

Hypoxia is rarely seen and usually suggests: severe croup or lower airways disease.

[8] What is the management of croup?

Glucocorticoids!

Glucocorticoids reduce symptoms, decrease the need for aerosolized epinephrine, result in fewer readmissions to the ED, and shorter ED and hospital stays.

Oral dexamethasone in a dose as small as 0.15 mg/kg is as effective as higher doses in decreasing the duration of symptoms and hospitalization.

Most places we work give 0.6 mg/kg/dose (to a max of 15 mg PO)

Aerosolized epinephrine, which reverses edema and relieves acute symptoms through vasoconstriction in the subglottic mucosa, should be given to children with stridor at rest.



It is a temporizing measure with a quick onset of action (<10 minutes) and duration of 1 to 2 hours.

“ Patients should be observed in the ED for 2 to 3 hours after epinephrine administration to ensure that stridor and respiratory distress do not recur.”

Adjuncts:

- ? heliox

If you need to intubate a sick croupier, be ready for a narrow airway (size down!) and have a good backup plan in place!

[9] Which children with croup require admission to hospital?

Several factors may impact the decision to admit a child with moderate croup, such as:

- *severity of symptoms at initial evaluation, persistence of respiratory distress, stridor at rest, hypoxia, poor response to treatment, dehydration, history suggesting airway disease or recurrent croup, young age (<6 months), high fever, and poor social support*

Lab and imaging studies rarely change management, unless you are looking for something else!

- **Complex med hx**
 - **Poor social support**
 - **Young < 6 months**
- **Sick**
 - **Resp distress/failure**
 - **Abnormal mental status**
 - **Persistent stridor at rest**
 - **TachC, tachyP**
- **Unusual - hypoxic, hyperpyrexia**
- **Dehydrated**

See Box 167.1

[10] What is the management of an upper airway foreign body? In a 6 month old? In a 6 year old?

Round foods (eg, peanuts, grapes, raisins, hot dogs) are especially common. Conformable objects are the most difficult to manage and remove, and balloons, including those made from examination gloves found in physicians' offices, are the objects most likely to result in death.

Helpful to consider if we're dealing with a partial vs. complete vs. lethal obstruction

Clinical signs of complete obstruction include poor air exchange, ineffective cough, severe



distress, and cyanosis. Foreign body aspiration that has settled in the lower airways may have subacute symptoms such as unilateral wheeze or may present later (days to years) as recurrent pneumonia. The sensitivity of a witnessed choking episode varies in the literature.

Partial obstruction:

- **Patient is adequately maintaining oxygenation and ventilation = let them maintain a position of comfort. DON'T TOUCH EM!**
- **Get the room ready if the obstruction becomes complete, while waiting for the OR.**
- **Don't paralyse them - because you may turn it into a complete obstruction!**

In a stable patient, a portable lateral neck radiograph and chest radiograph may be obtained as long as the patient is allowed to maintain a position of comfort. Radiographic findings suspicious for foreign body aspiration include radiopaque materials, mediastinal shift, emphysema, and atelectasis. A normal chest radiograph cannot rule out a nonradiopaque foreign body. CT scan and virtual bronchoscopy (a reformatted three-dimensional CT image that generates intraluminal views of the airway to the sixth- and seventh- generation bronchi) may be used to aid diagnosis in equivocal cases. Diagnostic flexible bronchoscopy is indicated with significant clinical suspicion of foreign body aspiration, despite normal imaging.

Complete obstruction:

- **<1 yr:**
 - **five back blows delivered between the shoulder blades, followed by five chest thrusts with the head held below the trunk.**
 - **Finger sweeps not recommended.**
- **>1 yr:**
 - **Heimlich maneuver for conscious children > 1 yr**
 - **CPR for unconscious children**
 - **If there is no chest rise with assisted ventilation with a bag-mask device, advanced airway techniques are indicated. Laryngoscopy should be performed to attempt visualization and foreign body removal with pediatric Magill forceps.**
 - **If foreign body cannot be visualized, it may be pushed distally into the right mainstem bronchus with an endotracheal tube to ventilate the nonobstructed portion of the lung.**

Lethal obstruction:

- **Jump right to advanced laryngoscopy with attempts to remove the foreign body**
- **If foreign body cannot be visualized, it may be pushed distally into the right mainstem bronchus with an endotracheal tube to ventilate the nonobstructed portion of the lung (consider taking the tube out to see if the foreign body became lodged in the tube - and then reinserting a new one)**

Wisecracks:

[1] List a differential diagnosis for stridor (8) (review)

1. Epiglottitis
2. RPA
3. Bacterial tracheitis



4. Foreign body
5. Croup
6. Vocal cord paralysis/dysfunction
7. Congenital laryngo-tracheomalacia (Downs, digeorge)
8. Webs/rings/esophageal hemangiomas
9. Extra-tracheal masses (double aortic arch, anomalous arteries, mediastinal masses/cysts)

[2] List 5 Xray findings of epiglottitis

Shoot that lateral neck xray!

1. Thumbprint sign (big epiG!)
2. Thickened aryepiglottic folds
3. Lack of air in the vallecula
4. Dilated hypopharynx
5. NORMAL (70% of xrays)

See figure 167.5

[3] Which infections are associated with croup?

Parainfluenza virus accounts for 50% to 75% of cases; respiratory syncytial virus, influenza A and B viruses, and rhinovirus cause the remainder.

[4] Describe the presentation and management of suspected bacterial tracheitis?

Bacterial tracheitis is three times more likely to cause respiratory failure than epiglottitis and viral croup combined. Bacterial tracheitis usually affects younger children, but may occur at any age.

Severe tracheal inflammation and production of thick purulent secretions!

The lining of the trachea forms a loosely adherent membrane that may become necrotic and slough, occluding the lumen. Microabscesses may be present in the tracheal mucosa.

Perforation and pneumomediastinum have been described. Traditionally, S. aureus (including MRSA) has been the organism primarily responsible for bacterial tracheitis but many causative bacteria have been reported.

Usually have a preceding viral prodrome and croup-like illness...then present as a toxic child with high fevers and rapidly worsening stridor that fails to improve with racemic epinephrine. Symptoms may overlap with those of croup and epiglottitis.

Features that suggest bacterial tracheitis include a viral prodrome followed by acute decompensation, symptoms atypical for croup (eg, high fever, cyanosis, severe

distress), poor response to usual treatment of croup (eg, steroids, aerosolized epinephrine), and inspiratory and expiratory stridor.

Labs = not helpful. Blood cultures = usually negative.

Findings on plain radiographs include subglottic narrowing, a ragged edge of the usually smooth tracheal air column, and a hazy density within the tracheal lumen, mimicking the appearance of airway foreign bodies. The epiglottis and supraglottic structures appear normal. In addition, the chest radiograph may reveal coexisting pneumonia. Bronchoscopy is diagnostic and therapeutic and should be performed emergently

Call ENT and get them to the OR.

Endoscopic tracheal débridement may result in significant clinical improvement and allow the child to be managed without intubation. Serial endoscopy may be needed to manage secretions. Endotracheal intubation is required in children with respiratory distress and hypoxia.

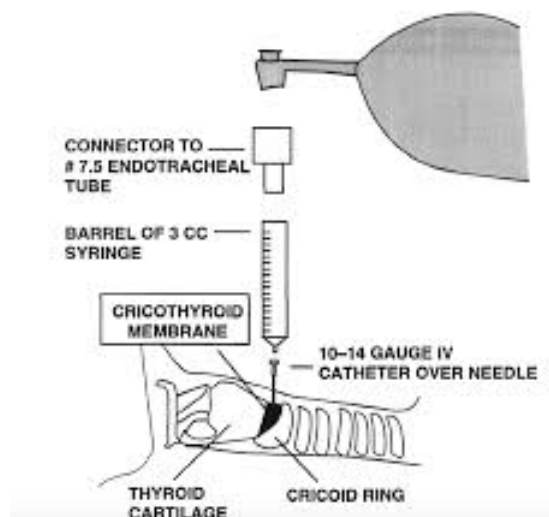
Patients should be admitted and receive supplemental oxygen, fluid resuscitation, and broad-spectrum antibiotics.

Abx options:

- Anti-staph = vanco or clinda
- Cefotaxime or ceftriaxone

[5] How do you handle the can't intubate can't ventilate (CICV) scenario?

Surgical cricothyrotomy is not recommended for infants and young children younger than 6 to 10 years. The anatomy changes with growth (ie, the larynx is high and cricothyroid membrane small), and it may be difficult to locate pertinent anatomy until a child is of school age.



“A 14- to 18-gauge angiocatheter (the size of catheter does not affect the rate of turbulent gas flow) is inserted in the cricothyroid membrane and connected to a 3-mL syringe (without the plunger) to a 7-mm endotracheal tube (ETT) adaptor (or a 3.0-mm ETT connector directly to the angiocatheter).”



Pizza 73

*Bag-mask ventilation (recommended in children < 5 years) can be performed through the ETT adaptor at 10 to 12 breaths/min to minimize barotrauma by **allowing for passive exhalation.***

Percutaneous transtracheal ventilation (in children \geq 5 years) is given at an oxygen flow rate of 1 L/min/year of age with a 1 :4 inspiration-to-expiration ratio (I:E).

Adults should receive oxygen from the wall source at 15 L/min (50–58 psi) and children at a rate of 10 to 12 L/min (25–35 psi). Complete airway obstruction does not allow for passive exhalation and necessitates a reduction of bag-mask ventilation rate to five or six breaths/min or I:E ratio of 1 :8 to 10 as a temporizing measure. Complications of needle cricothyrotomy include barotrauma and damage to adjacent structures.