



Chapter 95 – Large Intestine

Episode Overview:

1. List features that are typical for IBS.
(Describe the Rome IV criteria and list 4 medications used to treat irritable bowel syndrome)
2. What is the pathophysiology of diverticular disease?
3. List clinical presentations of diverticular disease.
4. How is diverticular disease managed in the ED? Which patients should be admitted to hospital? List 3 complications.
5. List the types and potential causes of large bowel obstruction.
6. What are the four types of GI volvulus? What are the risk factors for developing each type?
7. List the extra-intestinal manifestations of IBD.
8. What are the pathologic and clinical differences between UC and Crohn's?
9. List 4 categories of medical therapy for IBD and give one example for each.
10. Describe the radiologic features of toxic megacolon.
11. What the potential causes of toxic megacolon?
12. Which conditions are associated with the development of colonic ischemia? List 4 precipitants of ischemic colitis in the elderly and 3 in young patients
13. List 4 DDx for colitis
14. Differentiate between acute and chronic radiation proctocolitis in pathophys and clinical presentation

Wisecracks

- 1) What is Ogilvie's Syndrome? List 3 RFs
- 2) Compare AXR findings in SBO with LBO
- 3) What is the difference between each Cecal and Sigmoid volvulus on AXR? How is management different?
- 4) List 3 Perianal complications and 6 Extra-intestinal manifestations of Crohn's disease.
- 5) How does adult intussusception differ from peds

Rosen's in Perspective

Rosen's jumps right into the topics we're covering today! So let's just give you the list of what we'll be covering again!

- IBS
- Diverticular disease
- Volvulus
- Large bowel obstruction
- IBD
- Intussusception
- Colonic ischemia
- Radiation proctocolitis



1) List features that are typical for IBS.

This is a chronic, non-life threatening disorder - causing abdo pain and weird bowel habits. 10-15% prevalence, and it is thought to impair one's QOL more than diabetes or renal failure!!!

Its defined as a "functional, somatic syndrome" because there are no physical or lab features that clinch the diagnosis!

No known cause. Testing shows that people with IBS have abnormal electric rhythmic patterns and abnormal responses to stimulation. Often associated with anxiety, depression, FM, CFS, chronic pelvic pain, sexual abuse, menstrual cycle variations.

Routine laboratory studies (complete blood count, chemistries) are normal in IBS.

"Alarm" or atypical symptoms which are not compatible with IBS include:

- Rectal bleeding
- Nocturnal or progressive abdominal pain
- Weight loss
- Laboratory abnormalities such as anemia, elevated inflammatory markers, or electrolyte disturbances" -- Quotation from Uptodate 2017
- Nocturnal diarrhea, anorexia, onset > 50 yrs of age

However, here are features that are typical for IBS:

- *One out of three days of:*
 - Bloating
 - Abdominal pain (relieved with defecation)
 - Constipation OR diarrhea OR both
 - Upper GI symptoms (dyspepsia / nausea)
- *Mild abdominal tenderness*

The strict definition is made by the ROME IV criteria - check out the show notes!

Check out Box 85.2 - ddx for IBS based on symptoms - diarrhea, constipation, pain.

Describe the Rome IV criteria & list 4 medications used to treat irritable bowel syndrome

Rome III is no longer in! Here are the Rome IV criteria!

Table 1. Rome Criteria for IBS^{2,3}

Rome III Criteria for Diagnosing IBS:^a

Recurrent abdominal pain or discomfort at least 3 days/month in the last 3 months associated with two or more of the following:

- Improvement with defecation
- Onset associated with a change in frequency of stool
- Onset associated with a change in form (appearance) of stool

^aCriterion fulfilled for the last 3 months with symptom onset at least 6 months prior to diagnosis.

^b“Discomfort” means an uncomfortable sensation not described as pain.

Rome IV Criteria for Diagnosing IBS:^c

Recurrent abdominal pain, on average, at least 1 day/week in the last 3 months, associated with two or more of the following criteria:

- Related to defecation
- Associated with a change in frequency of stool
- Associated with a change in form (appearance) of stool.

^cCriteria fulfilled for the last 3 months with symptom onset at least 6 months before diagnosis.

Source: Lacy BE, et al. *Bowel Disorders. Gastroenterology. 2016;150:1393-1407; Rome III*

Pasted from: <https://irritablebowelsyndrome.net/clinical/new-rome-iv-diagnostic-criteria/>

Management:

- Dietary changes (no one actually knows what to consistently suggest!)
- MedS:
 - Dicyclomine (IBS-P)
 - Loperamide (IBS-D)
 - Rifaximin
 - Lactulose (IBS-C)
 - TCA's
 - SSRIs
- Peppermint oil
- Probiotics



2) What is the pathophysiology of diverticular disease?

“An affliction of middle age and Western civilization” - unknown before 20th century, etiology related to ?removal of the outer fiber on wheat kernels by the milling process. Supposedly 80% of people over 85 have diverticula.

The colon wall has weak points where the vasa recta run, it is thought that chronic low fiber stools (causing the colon to stressfully process stool), chronic inflammation, and altered bowel flora lead to diverticula.

These weak points are prone to herniation of the colonic mucosa - usually small, but can be > 1cm.

A couple important points:

- Diverticula doesn't equal diverticulitis (10-25% progress to itis though)
- Complicated diverticulitis:
 - **Any extension of inflammation beyond the pericolonic fat**
 - Abscess formation
 - Peritonitis
 - Intestinal obstruction (inflammatory ileus)
 - Fistula formation (to the bladder)

3) List clinical presentations of diverticular disease.

Symptoms show up when there is microinflammation and perforation of the sac.

**New frame shift: recently this is thought to be more of inflammatory condition - rather than infectious and obstructive.

Symptoms:

- Bloating
- Crampy pain
- Excessive gas
- Change in bowel habits

10-30% of people progress to diverticulitis (West = left side, Japan = right side)

ITIS presentation:

- LLQ pain (referred to groin or suprapubic)
 - RLQ pain in some!
- Peritonitis (if perforation)
- Dysuria / pneumaturia (colovesical fistula)
- Vomiting / distension (if obstructed)
- Feces / gas from vagina (colovaginal fistula)



A tentative diagnosis can be made clinically, but a CT scan is routinely performed to exclude alternative dx, or complicated diverticulitis. Empirical treatment can be initiated in the right context, especially if the person has been recently imaged to rule out other pathology.

4) How is diverticular disease managed in the ED? Which patients should be admitted to hospital? List 3 complications.

Take special care with the immunocompromised / elderly - they may have a perforation with less dramatic symptoms.

Management:

- **Diverticulosis**
 - High fiber diet, period.

- **Uncomplicated diverticulitis**
 - **Antibiotics** (?some controversy about this!!)
 - See Box 85.3 in Rosen's
 - Soft / liquid diet (for comfort - not mandatory)
 - NSAIDS / narcotics for pain relief (better Rx a stool softener or the constipation will worsen the disease!!)
 - Most young, immunocompetent patients can be managed with outpatient treatment and follow-up in 2-3 days.
 - Consider admission for IV abx if:
 - Inadequate po intake, high pain
 - No social supports
 - Elderly
 - Poor follow up

- **Complicated Diverticulitis**
 - Admission
 - Bowel rest
 - IV abx
 - Surgical consultation - may need percutaneous abscess drainage;
 - Fistulas and strictures may need surgical correction after the acute phase.

- **Definitive:**
 - Some surgeons may elect to do a single stage laparoscopic resection to remove sections of the colon

Complications:

- **Complicated diverticulitis:**
 - **Any extension of inflammation beyond the pericolonic fat**
 - Abscess formation
 - Peritonitis



- Intestinal obstruction (inflammatory ileus)
- Fistula formation (to the bladder)

- Bleeding - severe hemorrhage
 - Lower GI bleeding - 40% of it is caused by diverticulae (painless bleeding, often associated with NSAID use)

- Mis-diagnosis of colonic thickening as diverticulitis, when it is actually a malignancy

5) List the types and potential causes of large bowel obstruction.

Much less common > SBO; usually is a symptom of some underlying malignancy (>50% are due to colo-rectal CA)

Types:

Mechanical vs. pseudo-obstruction (Ogilvie's syndrome)

Causes:

- Malignancy (53%)
- Adhesions
- Volvulus (17%)
- Diverticular disease (12%)
- Fecal impaction
- Strictures (due to IBD)
- Hernias
- Pseudoobstruction (**the only type managed non-surgically)

Again, it's helpful to use the EXTERNAL vs INTERNAL approach for forming a DDx of the causes of LBO

Here is the pathophys:

“.....dilated with air and fluid that cannot be passed distally....When intraluminal pressure approaches systolic blood pressure, blood flow to the bowel wall is compromised...edema... decreased reabsorption of intraluminal fluid leads to dehydration...arterial flow to the bowel wall is compromised, ischemia and gangrene develop....translocation of bacteria..from a compromised bowel can lead to sepsis. Perforation of the bowel wall follows if the process is not interrupted.” - From Rosen's.

In these patients, the rectal exam is crucial - because you may find a hard mass or stool, which may explain the cause for the obstruction!



Management:

- Rehydration
- Electrolyte replacement
- Pain and nausea control
- Antibiotics (if perforated, sick, etc.)
- Gastric decompression and NPO
- Surgical consultation

6) What are the four types of GI volvulus? What are the risk factors for developing each type?

In general you can get a volvulus anywhere. Patients can present with a bowel obstruction pattern. Can get:

- Electrolyte disturbances secondary to third spacing / respiratory compromise from massive abdominal distention
- If left untreated bowel can get ischemic, gangrenous and perforate.

Pearl: Sigmoid volvulus account for 60% of all intestinal volvulus. So if you're a betting person that's the most common.

Gastric - Not large intestine...we know

2 types:

- Organo-axial volvulus is more common in adults, responsible for 60% of presentations
- Mesentero-axial volvulus is more common in children

Organo-axial volvulus

- more common of the two types in adults (60% of cases)
- RF: trauma or para-oesophageal hernia
- Pathophys: stomach rotates around long axis w/ antrum rotates anterosuperiorly fundus rotates posteroinferiorly

Mesentero-axial volvulus

- More common in peds
- Pathophys: rotation around short axis from the lesser to greater curvature displacement of antrum above gastro-oesophageal junction; stomach appears upside-down with the antrum and pylorus superior to the fundus
- plain films may show an intrathoracic stomach with two air fluid levels

Midgut

Caused by malrotated gut. Can be any age ***BUT ***

- approximately 75% of cases within a month of birth
- most within the first week
- 90% within 1 year



RFs: Gastroschisis / omphalocele / diaphragmatic hernia / duodenal or jejunal atresia

Cecal

- Requires congenitally abnormal mobile segment of cecum
- 10-25% of population have this anatomic variant
- RF: Usually needs coexisting trauma, adhesions, lymph nodes or malignancy, Pregnancy
- 20% risk for gangrene

Sigmoid

- Needs Long redundant section of sigmoid w/ narrow mesentery attachment to abdo wall
- The narrow attachment allows mesentery to twist on itself = luminal obstruction
- After obstruction, the proximal colon continues to force gas and liquid into the obstructed segment = sometimes massive dilation of the distal colon
- RF: A high fiber diet / Chronic constipation / Residents of long-term care facilities / neurologic or psychiatric disease

7) List the extra-intestinal manifestations of IBD.

- Inflammatory arthropathies/arthritis
- Iritis / uveitis / Episcleritis / Scleritis
- Erythema nodosum
- Pyoderma gangrenosum
- Aphthous stomatitis
- Ankylosing spondylitis
- Sacroiliitis
- Osteoporosis
- **Thromboembolic disease risk - 60% increased
 - DVT
 - PE
 - Cerebral sinus thrombosis
 - Ischemic heart disease
 - Mesenteric ischemia
- Peripheral neuropathy
- Primary sclerosing cholangitis (UC)

These extra-intestinal manifestations occur more frequently with Crohn's disease than UC.

8) What are the pathologic and clinical differences between UC and Crohn's?

These are the two similar, yet different diseases characterized by chronic, unpredictable relapsing inflammation of the GI tract. Thought to develop due to "immune system dysregulation in the GI tract".

Peak diagnosis at 15-35 yrs.



	UC	Crohn's disease
Pathologic features	<p>Superficial inflammation of the colon and rectum.</p> <p>*spares the small intestine*</p> <p>*superficial*</p> <p>*diffuse, continuous mucosal inflammation*</p> <p>*associated with PSC*</p> <p>*strong environmental component*</p> <p>Usually forms as a continuous lesion, but CAN also have skip lesions</p>	<p>Usually distal small intestine and proximal colon involved.</p> <p>*any part of the GI tract*</p> <p>*transmural inflammation*</p> <p>*multiple complications:</p> <ul style="list-style-type: none"> ● Strictures ● Abscesses ● Fistulae <p>*strong genetic component*</p> <p>*usually has "skip lesions"*</p> <p>*complex, fistulizing lesions*</p> <p>*granulomata*</p> <p>*affects younger patients and children*</p>
Clinical features (differences are underlined!)	<ul style="list-style-type: none"> ● Abdo pain ● Tenesmus ● Bloody diarrhea (4-6 or more stools per day) ● Weight loss ● Rectal bleeding ● Pallor / fatigue 	<ul style="list-style-type: none"> ● Abdo pain ● Tenesmus ● Bloody diarrhea (4-6 or more stools per day) ● <u>Nausea / vomiting</u> ● <u>Nocturnal diarrhea</u> ● <u>Fissures</u> ● <u>Anorectal abscesses</u> ● <u>Ulcerated hemorrhoids</u> ● <u>Strictures</u> ● <u>Growth and pubertal delay in children</u> ● Weight loss ● Rectal bleeding ● Pallor / fatigue ● <u>Peri-anal skin tags</u> ● Dry mucous membranes

9) List 4 categories of medical therapy for IBD and give one example for each.

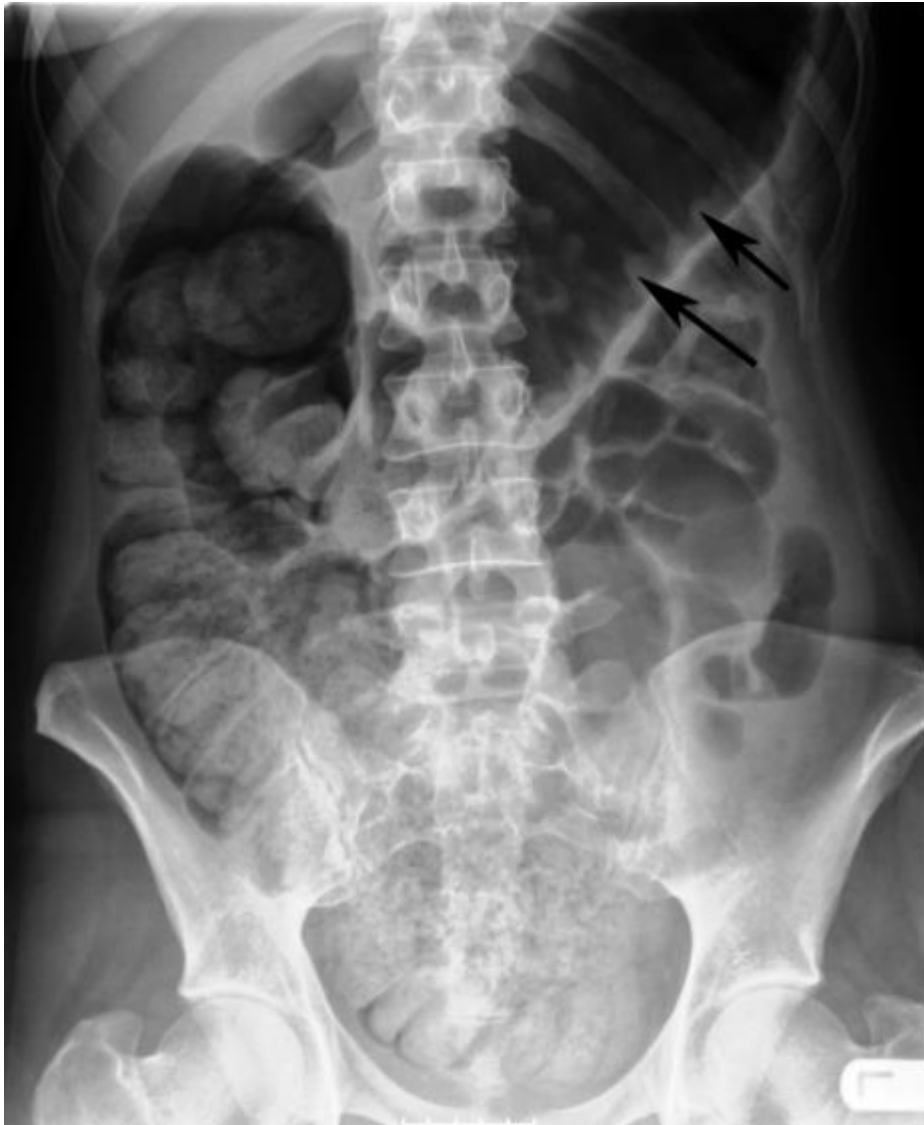1. Oral aminosalicylates (5-ASA, mesalamine)
2. Steroids (methylprednisolone, prednisone)
3. Immunosuppressants (cyclosporine)
4. Antibiotics (Flagyl + Cipro)

25% of people with UC may need surgery.

10) Describe the radiologic features of toxic megacolon.

Radiographic findings on plain abdominal films:

- dilatation of the right colon greater than 6 centimeters,
- dilatation of the transverse colon;
- absence of normal colonic haustral markings,
- air-filled crevices between large pseudopolypoid projections extending into the colonic lumen.



Copied from: <http://www.radpod.org/2007/07/05/toxic-megacolon/>



11) What the potential causes of toxic megacolon?

Toxic megacolon (pathologic dilatation due to inflammation, paralysis of the smooth muscle layers) may occur as a complication of IBD, infectious colitides of diverse etiology, ischemic colitis, volvulus, diverticulitis, and obstructive colon cancer.

Most people present with multiple days of loose bloody stools (>10 /day), fever, abdominal pain, dehydration, distension, anorexia.

Often may be triggered by: anticholinergics, antimotility agents, narcotics, antidepressants.

Management (copied from Uptodate - 2017)

“Medical therapy is the first line of treatment for patients with IBD and toxic megacolon and includes fluid resuscitation and correction of laboratory abnormalities, administration of broad-spectrum antibiotics, intravenous corticosteroids, complete bowel rest, bowel decompression with a nasogastric or long intestinal tube, and a surgical consultation.

Medical therapy is the first line of treatment for patients with toxic colon from *C. difficile* and includes fluid resuscitation and correction of laboratory abnormalities, discontinuation of the offending antibiotic, oral or tube administration of [vancomycin](#) and intravenous [metronidazole](#), complete bowel rest, bowel decompression with a nasogastric or long intestinal tube, and a surgical consultation. “

Make sure you correct any hypokalemia and hypomagnesemia

12) Which conditions are associated with the development of colonic ischemia? List 4 precipitants of ischemic colitis in the elderly and 3 in young patients

Very tough diagnosis to make!

Usually a non-occlusive mechanism. Most common spot is left colonic segment. (but can also affect the right segment due to pathology leading to SMA occlusion)

Elderly:

1. CHF
2. Vasoactive drugs (digoxin, sumatriptan, pseudoephed)
3. Atherosclerosis
4. Renal failure
5. Thrombophilia and infectious (STEC)
6. Post-operative cardiac sx



Young patients:

1. Collagen vascular disease
2. Heme disorders
3. Long distance running
4. Cocaine abuse

13) List 4 DDx for colitis

- Infectious colitis
 - STEC (E coli o157h7)
 - C. Diff
 - Amoeba
- Ischemic colitis
- Radiation colitis
- Diverticular disease
- Appendicitis
- Inflammatory cancer
- In Kids:
 - Henoch Schonlein Purpura
- Celiac disease
- Toxic megacolon

14) Differentiate between acute and chronic radiation proctocolitis in pathophys and clinical presentation

****"Radiation proctocolitis (RP) is a common side effect of radiation therapy, occurring in 50% to 75% of patients receiving radiation to the pelvis"****

Symptomatic treatment for both: steroid enemas, antibiotics for suspected infection, surgical consult for perforation

Acute proctocolitis: abdominal and rectal pain, diarrhea, bleeding, and tenesmus

Time course: within 6 weeks after a course of radiation therapy

Pathophys: intestinal mucosa is rapidly overturned → Radiation slows the regrowth but does not affect sloughing rate → This leads in gaps of coverage that coalesce into ulcerations

Once radiation stops, healing begins and usually self resolves in several weeks

Chronic proctocolitis: Can be similar to acute OR insidious onset, with a variety of presentations, including ulcerative disease, stricture, obstruction, fistula, bowel perforation or fecal incontinence

Time course: can occur at anytime post therapy



Pathophys: TOTALLY DIFFERENT THAN ACUTE. Its all about the endarteritis here... combined with abnormal collagen tissue deposition. Net result: decrease gut perfusion causing ischemia, scarring and decrease bowel lumen diameter.

Wisecracks:

1) What is Ogilvie's Syndrome? List 3 RFs.

Remember Episode 92: Small intestine - 3 causes of SBO =

- Mechanical
- Neurogenic
- Pseudo-obstruction**

Here we are talking about the last. Acute intestinal or colonic pseudo-obstruction (Ogilvie's syndrome).

- Characterized by acute dilatation of the intestine in the absence of an anatomic lesion that obstructs the flow of intestinal contents
- Usually its the right hemi colon with possible extension to rectum.
- More common in old men. Pathogenic mechanism : unknown. Thought to be some disruption of autonomic nervous system and pacemaker cells of cajal.

Common associated risk factors:

- Trauma, especially fractures
- Surgery especially involving spinal anesthesia
 - Major orthopedic surgery / Obstetrical surgery / Pelvic / abdominal / cardiothoracic surgery
- Severe medical illness (eg pneumonia/myocardial infarction/heart failure)
- Neurologic conditions
- Chemotherapy
- Retroperitoneal pathology (ie malignancy or hemorrhage)
- One of the above plus metabolic imbalance or medication administration (eg, narcotics, phenothiazines (think methylene blue), calcium channel blockers, alpha-2-adrenergic agonists, epidural analgesics)

Don't forget about other causes of colonic dilatation: mechanical or toxic megacolon!

2) Compare AXR findings in SBO with LBO

According to [Radiopedia](#):

SBO

Abdominal radiographs are only 50-60% sensitive for small bowel obstruction. In most cases, the abdominal radiograph will have the following features:

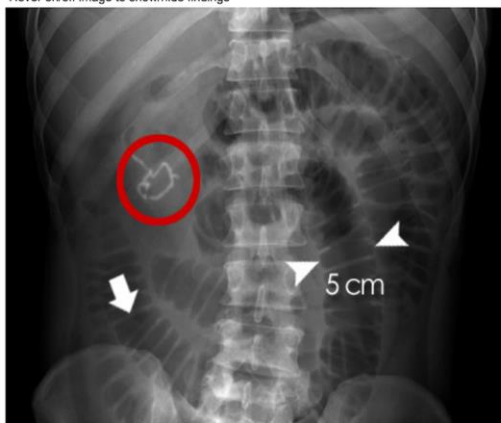- Dilated loops of small bowel proximal to the obstruction
- Predominantly central dilated loops
- Three instances of dilatation > 2.5-3 cm
- Valvulae conniventes are visible
- Air-fluid levels if the study is erect, especially suspicious if
 - >2.5 cm in length
 - In same loop of bowel but at different heights

High grade obstruction may also present with the following features:

- Gasless abdomen: gas within the small bowel is a function of vomiting, NG tube placement and level of obstruction
- String-of-beads sign: small pockets of gas within a fluid-filled small bowel

Small bowel obstruction - features

Hover on/off image to show/hide findings

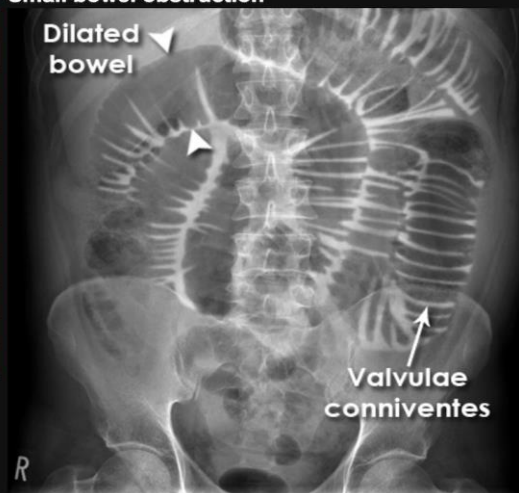


Click image to align with top of page

Small bowel obstruction - features

- ◆ Centrally located multiple dilated loops of gas filled bowel (**arrowheads**)
- ◆ Valvulae conniventes (**arrow**) are visible - confirming this is small bowel
- ◆ Evidence of previous surgery - note the anastomosis site (**red ring**) - this suggests adhesions is the likely cause of obstruction (confirmed at surgery)

Small bowel obstruction



Small bowel obstruction

- ◆ Features of small bowel obstruction include the central position of gas-filled and distended loops of bowel.
- ◆ The white lines passing across the full width of the bowel are 'valvulae conniventes' - these are only found in the small bowel.

LBO ¹

Large bowel obstructions are characterised by colonic distension proximal to the obstruction, with collapse distally.

Cut-off for what constitutes dilatation

- Colon = 6cm
- Caecum = 9cm

Xray findings:

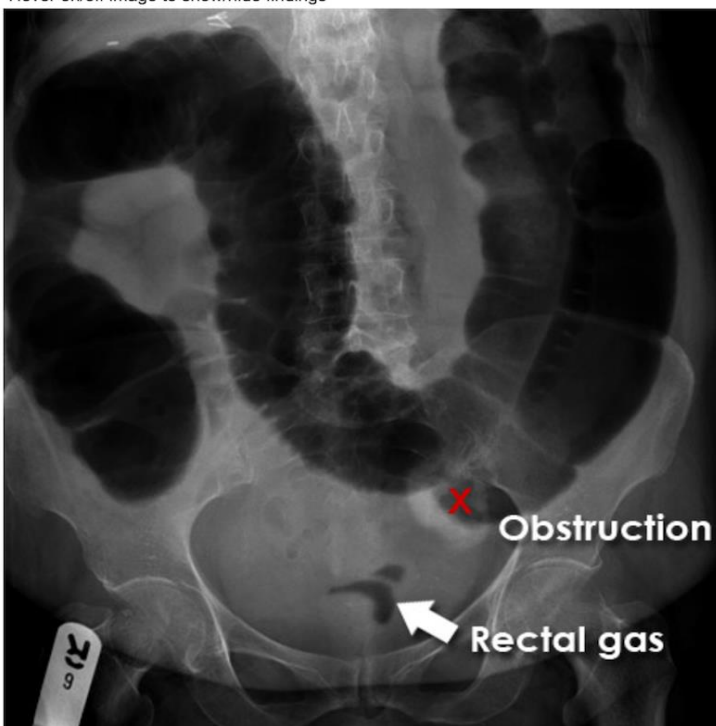- colonic distension: gaseous secondary to gas-producing organisms in faeces
- collapsed distal colon
- small bowel dilatation, depends on
 - duration of obstruction
 - incompetence of the ileocaecal valve

Don't forget to look for signs of ischemia:

- intramural gas (pneumatosis coli)
- portal venous gas
- free intra-abdominal gas (pneumoperitoneum)

Large bowel obstruction

Hover on/off image to show/hide findings



Click image to align with top of page

Large bowel obstruction

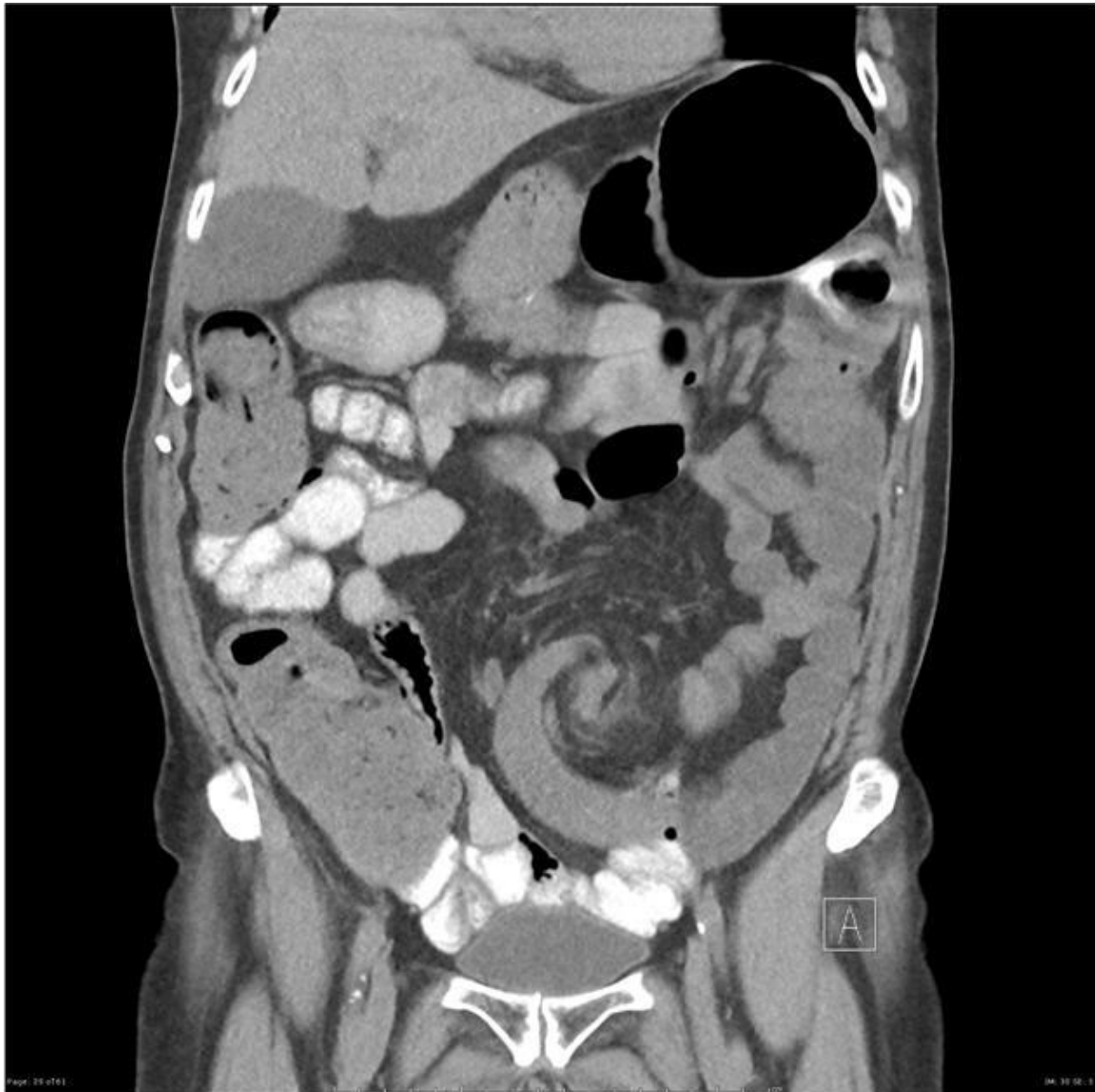- ◆ Here the colon is dilated down to the level of the distal descending colon. There is the impression of soft tissue density at the level of obstruction (X). No gas is seen within the sigmoid colon.
- ◆ Obstruction is not absolute in this patient as a small volume of gas has reached the rectum (arrow).
- ◆ An obstructing colon carcinoma was confirmed on CT and at surgery.

¹ Source: http://www.radiologymasterclass.co.uk/tutorials/abdo/abdomen_x-ray_abnormalities/pathology_large_bowel_obstruction

3) What is the difference between each Cecal and Sigmoid volvulus on AXR? How is management different?

Punchline: Very hard to differentiate between the two on plain radiographs. CT is WAY better for not missing volvulus and looking for the broader differential.

Look for the whirl sign, Source: [Radiopedia](http://radiopedia.com)



Cecal Volvulus

majority of patients (90%) have abdominal pain, but clinical triad of abdominal pain, distention, and constipation is not so bueno (inconsistent). Patterns of presentation vary on a spectrum similar to that for sigmoid volvulus. Vomiting is seen in only 50% of patients.



Radiographs : 50% sensitivity...

- Dilated cecum w/ possible air fluid level.
- Small bowel often is distended as well.
- In contrast, with sigmoid volvulus, the distal colon should have a paucity of gas
- The classic coffee bean sign, a large oval gas shadow with a line down the middle representing bowel bent over on itself, may be seen in the midabdomen.
- Free air = perforation
- Cecal volvulus is often diagnosed only at surgery.

Sigmoid

More classic triad of abdominal pain, distention, and constipation

Radiograph:

- grossly distended loop of colon (no haustral markings)
- “bowel may have the appearance of a bent inner tube.”
- Perforation = Free air may on upright chest radiograph or lateral decubitus radiograph
- Can have false negative secondary to obscuring bowel gas
- Contrast enema can help: shows tapering point of torsion, i.e “bird’s beak” appearance

Management:

Cecal: surgery (open vs laparoscopic)

Sigmoid: endoscopic reduction versus surgery

4) List 3 Perianal complications and 6 Extra-intestinal manifestations of Crohn’s disease.

Perianal:

- Anal Fissures
- Skin tags
- Perianal Fistula
- Anorectal Abscess
- Anal Stenosis
- Ulcerated Hemorrhoids
- Elevated risk for adenocarcinoma in fistula tract and recurrent stenosis

Extra-intestinal

- MSK (Arthritis, ankylosing spondylitis, isolated joint, Hypertrophic osteoarthropathy - Clubbing, periostitis)
 - Miscellaneous - Osteoporosis, aseptic necrosis, polymyositis, osteomalacia



- Skin and mouth
 - Reactive lesions - Erythema nodosum, pyoderma gangrenosum, aphthous ulcers, vesiculopustular eruption, cutaneous vasculitis, neutrophilic dermatosis, metastatic Crohn disease, epidermolysis bullosa acquisita
 - Specific lesions - Fissures and fistulas, oral Crohn disease, drug rashes
- Nutritional deficiency - Acrodermatitis enteropathica (zinc), purpura (vitamins C and K), glossitis (vitamin B), hair loss and brittle nail (protein)
- Hepatobiliary
 - Specific complications - Primary sclerosing cholangitis (PSC) and bile duct carcinoma, small duct PSC, cholelithiasis
 - Associated inflammation - Autoimmune chronic active hepatitis, pericholangitis, portal fibrosis and cirrhosis, granuloma in Crohn disease
 - Metabolic - Fatty liver, gallstones associated with ileal Crohn disease
- Ocular : Uveitis iritis, episcleritis, scleromalacia, corneal ulcers, retinal vascular disease, retrobulbar neuritis, Crohn keratopathy
- Metabolic: Growth retardation in children and adolescents, delayed sexual maturation
- Thromboembolic disease
 - **Thromboembolic disease risk - 60% increased
 - DVT
 - PE
 - Cerebral sinus thrombosis
 - Ischemic heart disease
 - Mesenteric ischemia
- Peripheral neuropathy

5) How does adult intussusception differ from peds

Adults:

- Vague, undifferentiated presentations - age 65 yrs
- Usually cause by a mass (60% benign neoplasms, 30% malignant)
- CT diagnosis
- Need surgery usually
- Not so happy endings

Kids:

- Vague, undifferentiated presentations, but second most common cause of abdominal pain in kids next to appendicitis (often age 4-10 months?)
- Usually unknown cause (viral adenopathy?)
- Diagnosed with U/S
- Usually ileocolic (at the cecal valve)
- Usually reduced with air/hydrostatic enemas (80% of cases)
- Good endings