



Chapter 71 – Ophthalmology Part B

Episode Overview:

1. List 10 causes of ↓ vision post blunt eye trauma
2. What historical features are concerning for intra-ocular foreign body?
3. List 4 options for treatment of corneal abrasions
4. Describe the management of traumatic hyphema
5. What causes the finding of a 'second pupil' post-trauma?
6. Describe the physical findings of globe rupture and describe management
7. List 5 indications for ophtho consultation for eyelid lacerations
8. Describe diagnosis and treatment for orbital floor fractures:
 - a. List 2 findings on X-ray of orbital floor fracture
 - b. List indications for surgical repair of orbital floor fracture
9. Describe the clinical findings of retrobulbar hemorrhage and the steps in performing lateral canthotomy
10. List 3 complications of ocular trauma

Rosen's in Perspective

- If you haven't listened to Episode 21 and 22, check them out!
 - If you want to review how to do an eye exam...

1) List 10 causes of ↓ vision post blunt eye trauma

- 1) Globe rupture
- 2) Hyphema
- 3) Lens subluxation / dislocation
- 4) Iridodialysis
- 5) Traumatic uveitis
- 6) Vitreous hemorrhage
- 7) Retinal injury
 - a. Hemorrhage, detachment, tear, "commotio retinae" (Berlin's edema)
- 8) Orbital wall fracture
- 9) Retrobulbar hematoma
- 10) Optic nerve injury
 - a. Causing avulsion, transection, compression, contusion of the optic nerve

Lens subluxation and dislocation

- May occur in minor trauma in patients with:
 - Marfan syndrome, homocystinuria, tertiary syphilis, connective tissue disease
- Symptoms:
 - **Monocular** diplopia / visual distortion / blurry vision /
- Signs:
 - Dec. VA / subluxed lens after dilation / shimmering of the iris
- Treatment: Ophtho consult



2) What historical features are concerning for intra-ocular foreign body?

Orbital and Intraocular foreign bodies

- Need clinical suspicion
 - Hammering, grinding, metalworking, machine operating
 - Explosions, firearm use
- Need CT diagnosis
- Treatment:
 - Based on ophtho opinion;
 - Inert bodies (plastic, glass, metals) may be left in
 - Organic and oxidizing material needs removal
 - Need eye shielding
 - Need IV ceftazidime
 - Need topical erythromycin

3) List 4 options for treatment of corneal abrasions

Mechanical Corneal Abrasions

- FB sensation, photophobia, decreased VA
- Pain relief with topical anesthetics diagnose the problem as corneal injury
- Watch for a positive Seidel's sign - which suggests a corneal perforation
- Treatment
 - Full lid eversion and examination!
 - Contact lenses shouldn't be worn until the abrasion is healed (3-5 days)
 - Eye patches aren't needed!
 - Cycloplegic prn
 - e.g. Tropicamide
 - Topical antibiotics - probably only needed for people who wear contact lenses
 - Pseudomonal coverage if contact lens wearer (tobramycin 0.5% 1-2 drops q 4hrs)
 - Topical analgesics:
 - Ketorolac 0.5% QID
 - Diclofenac 0.1% QID
 - Tetanus immunization only needed for any "tetanus-prone" injury with dirt and organic matter
 - NO cases of tetanus have been documented from simple corneal abrasions
- Symptoms should resolve by 24-72 hrs

Corneal foreign bodies:

- High risk features for perforation
 - Grinding, drilling, saws, hammering --> consider CT orbits
- Treatment
 - full eye exam



- Topical anesthetic
- Remove:
 - Irrigation, moistened cotton tip applicator
 - 18 ga BLUNT needle
- Rust ring:
 - Needs 24 hrs to prime and move to the surface of the cornea
- Referral
 - Deeply embedded, in the visual axis

Conjunctival foreign body

- Same approach as corneal but less risk of affecting vision
- Use topical phenylephrine to help reduce the bleeding on removal

Subconjunctival hemorrhage

- Common occurrence with valsalva or spontaneously
- Should be PAINLESS, not affecting vision, with no photophobia
- Should not tract into the limbus
- If bilateral:
 - Think about bleeding diathesis
- Treatment: cold compresses x 24 hrs
- Resolves in 2-4 weeks

4) Describe the management of traumatic hyphema

Traumatic hyphema

- Due to injury to the blood vessels in the iris or ciliary body
- Amount varies from miniscule (all what can be seen by slit lamp -- > full "8 ball")
- Symptoms:
 - Pain / photophobia / dec. VA / mildly elevated IOP
- Management:
 - Need admission if:
 - >50%, decreased VA, increased IOP, sickle cell disease
 - e.g. "really big, really bad, gonna pop, or patient factors"
 - Treatment (if no sickle cell disease)
 - Topical beta blocker
 - Topical alpha-agonist / carbonic anhydrase inhibitor
 - Acetazolamide or IV mannitol
 - +/- Cycloplegics and steroids
 - At risk for:
 - Rebleeding in 2-5 days
 - Corneal blood staining
 - Glaucoma (due to angle recession)
 - Synechia formation
 - Those with hemoglobinopathies:

- Sickle cell disease / trait ; thalassemia are at increased risk for complications
 - AT high risk for INCREASED IOP
 - Need coordinated intensive treatment with ophthalmology

Traumatic iridocyclitis (uveitis)

- Caused by blunt injury to the globe --- > ciliary spasm
- Symptoms:
 - Photophobia / deep aching pain
- Signs
 - Perilimbal conjunctival injection (ciliary flush)
 - Cells in the ant. chamber
 - Flare (protein content)
 - Non-dilating pupil.
 - Direct and consensual photophobia
- Treatment:
 - Long acting cycloplegic (homatropine)
 - Prednisolone

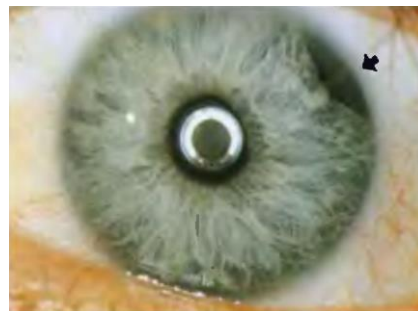Traumatic mydriasis and miosis

- Need to rule out altered LOC or cranial nerve defect before a pupillary defect is diagnosed
- Results from small tears in the pupillary muscle

5) What causes the finding of a 'second pupil' post-trauma?

Iridodialysis

- Tearing of the iris root from the anterior ciliary body --> leads to second pupil
- Usually occurring after blunt trauma
- Watch for hyphema
- Symptoms: monocular diplopia
- Needs immediate optho. consult;
 - Bed rest
 - Keep intraocular pressure low
 - Eye shielding





6) Describe the physical findings of globe rupture and describe management

Scleral globe rupture

- Occurs in setting of blunt or penetrating trauma
- May be obvious (contents oozing) or subtle
- Symptoms:
 - Dec. VA / pain
- Signs:
 - Bloody chemosis / severe subconjunctival hemorrhage /
 - Tear drop pupil
 - RAPD / poor VA / no red light reflex
 - Do NOT do tonometry
- CT:
 - Only 75% sens.
- Treatment:
 - Eye shield
 - Head of bed > 45 degrees
 - NPO
 - Antiemetics
 - Analgesics
 - Antitussives
 - Broad spectrum abx:
 - Ceftriaxone & gentamicin & vancomycin

7) List 5 indications for ophtho consultation for eyelid lacerations

Laceration of the eyelids

- Need to search for a penetrating injury and foreign body
- Simple superficial lacerations not involving the eyelid margin can be treated in emerg.
 - Simple 6-0 / 7-0 interrupted sutures removed in 3-5 days
- **Complex lacerations needing referral:**
 - **Lac of the lid margin**
 - **Lac. of the canalicular system (medial eyelid)**
 - **Lac. involving the levator or canthal tendons**
 - **Lac. through orbital septum**
 - **Presence of orbital fat*** = no subcutaneous fat in the eyelids so the fat is likely from a globe injury**
 - **Lac. with tissue loss**

Conjunctival / corneal / scleral lacerations

- Small superficial conjunctival lacerations = no suturing, heal well,
 - Topical antibiotics



- Larger (> 1cm)
 - Need repair
- Corneal/scleral lacerations
 - Full thickness if:
 - Loss of anterior chamber depth, teardrop-shaped pupil, blood in anterior chamber, seidel's signs
 - Treated:
 - As globe rupture with ophtho. consult

8) Describe diagnosis and treatment for orbital floor fractures

Orbital wall fractures

- The orbital floor is the weakest point = it's the emergency pressure release to prevent globe injury
 - Fracture can lead to entrapment of inferior rectus/oblique muscle; orbital fat or connective tissue
 - Signs:
 - Enophthalmos, ptosis, diplopia, anesthesia of cheek and upper lip, limitation of upward gaze
 - Diagnosis: CT orbits is the preferred test
 - Treatment:
 - If fracture into an infected sinus:
 - Decongestants +/- steroids
 - Clavulin
 - Ice packs
- Medial orbital wall (enter the ethmoid sinus)
 - Signs
 - Orbital emphysema and epistaxis
 - Diplopia
- Key instructions:
 - Don't blow your nose or sneeze
 - Watch for signs of infection
 - Watch for double vision or visual loss
 - Can be discharged home if:
 - No globe rupture
 - No visual impairment

a) List 2 findings on X-ray of orbital floor fracture

- Plain x-ray films have limited utility:
 - On x-ray film, the teardrop sign, a bulge extending from the orbit into the maxillary sinus,
 - An air-fluid level in the maxillary sinus are indirect signs of orbital floor injury

b) List indications for surgical repair of orbital floor fracture

- Surgery for:
 - Persistent diplopia +/- loss of visual acuity
 - Cosmetic concerns that persist after 7-10 days when swelling has subsided
 - Don't need "in ER" consultation, can be seen in f/u in 1-2 weeks
 - Consider admission and quicker consultation if the fracture extends through an infected sinus

9) Describe the clinical findings of retrobulbar hemorrhage and the steps in performing lateral canthotomy

Retrobulbar hemorrhage

- Causes acute rise in IOP which can compress the optic nerve
 - Compression of the Central retinal artery and optic nerve
- Signs
 - Proptosis
 - Limited EOM
 - Visual loss
 - Increased IOP
- *****Don't wait for a CT scan if you are suspicious******
- Treatment:
 - Carbonic anhydrase inhibitor
 - Topical beta blockers
 - Mannitol 1-2 g/kg
 - LATERAL CANTHOTOMY

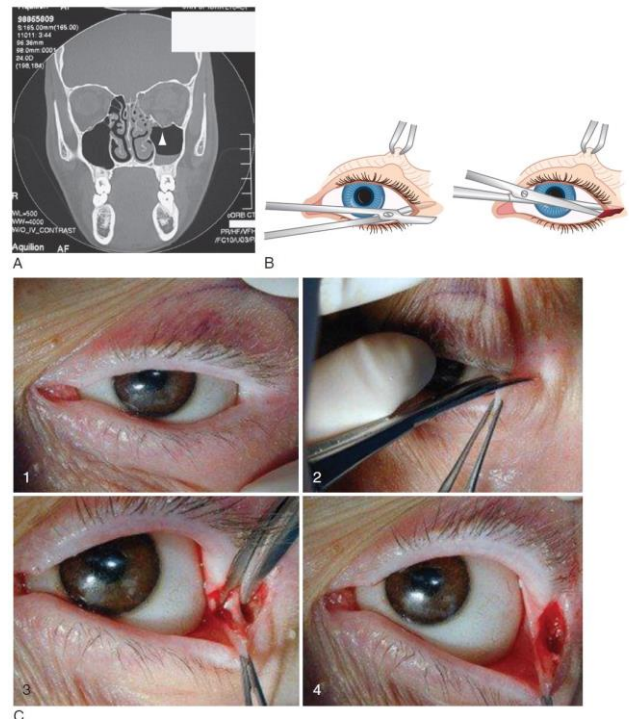


Figure 71-3 A, Facial computed tomography scan showing left inferior orbital fracture with blood in maxillary sinus. B, Lateral canthotomy. C, (1) Preoperative view of orbit. (2) Incision for lateral canthotomy. (3) Identification and incision of inferior canthal tendon, completing cantholysis. (4) View after lateral canthotomy and inferior cantholysis, creating maximal immediate decompression by allowing eyeball and orbital contents to move anteriorly. (A, Courtesy University of Iowa Department of Ophthalmology, http://webeye.ophth.uiowa.edu/eyeforum/images/floorfx_08232004.jpg. C, From Ramakrishnan VR, Palmer JN: Prevention and management of orbital hematoma. Otolaryngol Clin North Am 43:789-800, 2010.)



The procedure:

1. Ensure the patient has one of the absolute / relative indications for this procedure
 - a. DIP A CONE
2. Informed consent
3. Don PPE
4. Wash the area with saline
5. 1-3 ml 1% lidocaine with epi. Into the lateral canthus (consider light procedural sedation)
6. Devascularize with hemostat
7. Incise the lateral canthus
8. Pull lower lid down and localize the *inferior canthal tendon* - then cut it with iris scissors
9. Reassess, and repeat for the superior canthal tendon if needed

Table 1. Indications and contraindications for lateral canthotomy and cantholysis^a (LCC)

Primary indications

- Decreased visual acuity
- Intraocular pressure > 40 mm Hg
- Proptosis

Secondary indications

- Afferent pupillary defect
- Cherry red macula
- Ophthalmoplegia
- Nerve head pallor
- Eye pain

Contraindications

- Globe rupture

Table copied from: <https://www.ncbi.nlm.nih.gov/pubmed/17637149>

See:

<https://first10em.com/2015/04/01/procedure-lateral-canthotomy/>

And

<http://webeye.ophth.uiowa.edu/eyeforum/tutorials/lateral-canthotomy-cantholysis.htm>

For videos explaining it!

10) List 3 complications of ocular trauma

- **Post-traumatic corneal ulcers:**
 - Can develop post-trauma due to bacterial or fungal infection
 - Signs: white/gray cornea
 - Hypopyon
 - Treatment:
 - Ophtho referral
 - Cycloplegic
 - Topical antibiotics
- **Endophthalmitis**
 - Infection of the DEEP structures of the eye
 - Anterior, posterior, vitreous chambers of the eye
 - Symptoms:
 - PAIN, and vision loss
 - Signs:
 - Decreased VA, chemosis, hyperemia, hazy chambers



- Risk factors:
 - Blunt globe rupture, penetrating eye injury, foreign bodies, ocular surgery
- Treatment:
 - IV ceftazidime, IV vancomycin
 - intraocular gentamicin + clindamycin
- **Sympathetic ophthalmia**
 - Famous disease: thought to have affected Louis Braille who was blind by age 5!
 - http://eyewiki.aao.org/Sympathetic_Ophthalmia
 - Inflammation that occurs in the UNINJURED EYE weeks to months after opposite eye injury
 - An autoimmune response to the normal uveal tissues
 - Symptoms:
 - Pain, photophobia, dec. VA
 - Treatment:
 - Steroids, immunosuppressive agents