



## Chapter 44 – Neck Trauma

### Episode Overview:

- 1) Describe the landmarks and structures using the Zones of the neck & the Triangles of neck
- 2) List 6 hard and 6 soft signs of penetrating neck trauma. What are the indications for immediate OR vs CTA in managing penetrating neck trauma
- 3) Describe an approach to managing acute neck trauma in the ER
- 4) Describe the management of venous air embolism
- 5) Describe techniques for airway management in penetrating neck trauma
- 6) Describe the management of suspected pharyngoesophageal trauma. What are signs of esophageal injury?
- 7) List 3 hard signs of laryngotracheal trauma and describe airway management dilemmas

### Wisecracks:

- 1) Differentiate between choking, hanging and strangulation
- 2) Define judicial and non-judicial hanging and describe expected injury patterns

### Rosen's in Perspective

- Wide range of complications from minor wounds to severe hemorrhage, neurologic injury, to airway compromise
- Apparently stable patients can harbour life threatening injuries

Three mechanisms of neck trauma:

1. Blunt
2. Penetrating
3. Strangulation / near hanging

Four anatomic injury areas:

1. Laryngotracheal - airway
2. Pharynx oesophageal - digestive tract
3. Vascular system
4. Neurologic system

### Principles of Disease

LOCATION	NUMBER (1275 TOTAL)	PERCENTAGE*
Arterial	320	12.8
Venous	281	11.3
Tracheolaryngeal	253	10.1
Pharyngoesophageal	240	9.6
Spinal cord	76	3
Neurologic, other	85	3.4
Thoracic duct	20	0

From McConnell DB, Trunkey D: Management of penetrating trauma to the neck. Adv Surg 27:97, 1994.

\*Incidence based on other reported series.



Penetrating trauma:

- Aetiologies:
  - GSW's:
    - High velocity: rifles > 2000 ft/s
      - Have very predictable direct pathways through tissue: produce a large blast effect
      - Can produce a cavitation effect (if >1100 ft/s)
      - *Cavitation*: an immediate release of kinetic energy as the bullet enters the tissue- creating extensive soft tissue damage.
    - Low velocity: handguns and air rifles:
      - Bone penetration occurs at 300 ft/s
      - These produce erratic pathways: with no direct relationship between entrance and exit wounds
    - stab wounds, impalement, shrapnel
      - Low energy injuries produce much less severe mechanisms of injury
      - Many of these do not need surgical management
      - Mortality 2-6% - from exsanguination

Blunt trauma:

- From MVCs, clothesline injuries, strangulation, sports injuries
  - Blunt vascular injuries are RARE, but often missed
  - Blunt injuries to the aero digestive & vascular tracts are rare - but present in a delayed way with devastating consequences

## 1) Describe the landmarks and structures using the Zones of the neck & the Triangles of neck

ANATOMY:

- Densely packed tissues with vital structures: vascular injury can be tamponaded by fascial planes and neighbouring structures can be massively distorted.
- Two fascial layers cover the neck:
  - a. *Superficial fascia:*
    - *This layer COVERS the platysma muscle, and is just below the skin*
    - Because the platysma muscle is sandwiched between both fascial layers: its violation suggests deep structure injuries
    - Blind probing of neck wounds is discouraged - due to clot disruption possibilities
  - b. *Deep cervical fascia*
    - Has three parts: all three form to make the carotid sheath
      - Investing layer:
        - Surrounds the neck and encases SCLM and trapezius muscles
      - Pre-tracheal layer:
        - Adheres to the cricoid and thyroid cartilages → travels to sternum and inserts on the anterior pericardium
        - \*\*\*\*\*missed aerodigestive injuries: can lead to mediastinitis

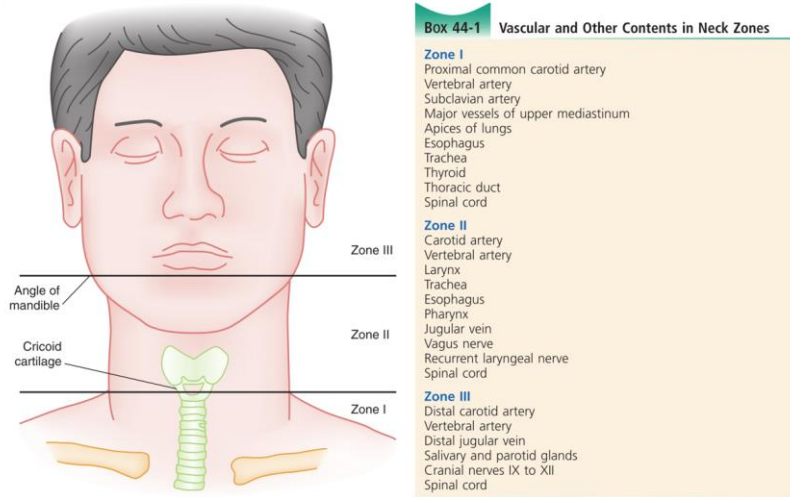


Figure 44-1. Zones of the neck.

- Pre-vertebral layer:
  - Envelops the pre-vertebral muscles to form the Axillary sheath and covers the subclavian artery

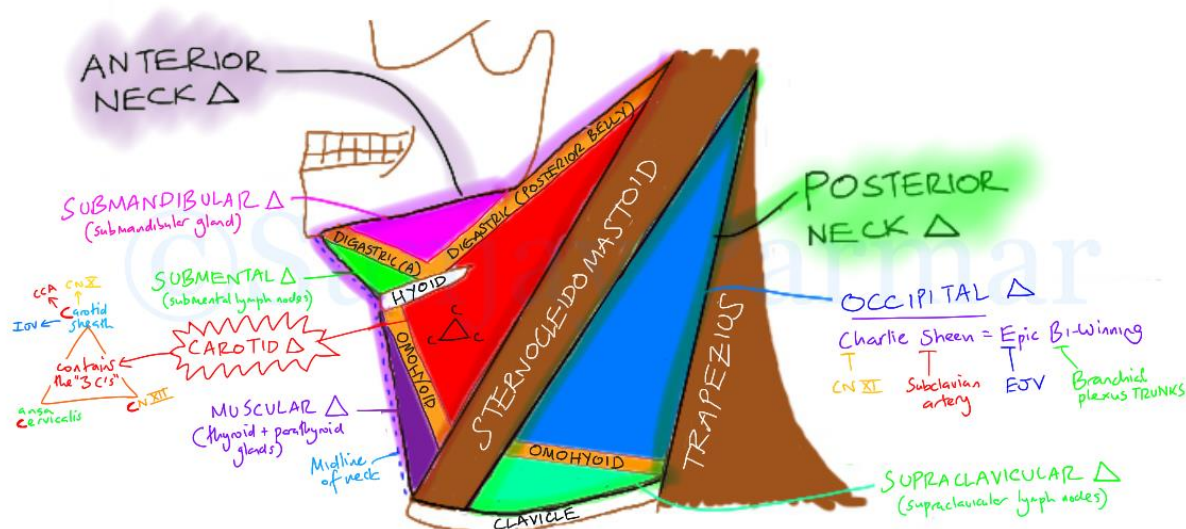
Two ways of describing the neck:

#### ZONES APPROACH

- I: thoracic outlet
  - Sternal notch/clavicles -> cricoid cartilage
  - Thoracic, mediastinal, neck structures affected.
- II: mid neck
  - Cricoid cartilage → angle of the mandible
  - Easier surgical control and exploration
- III : upper neck:
  - Angle of the mandible to the base of the skull
  - Difficult surgical access and control

#### TRIANGLES APPROACH

- Anterior triangle:
  - Contains neurovascular. And aero digestive tracts:
    - Midline -- sternocleidomastoid muscle -- lower edge of the mandible
- Posterior triangle:
  - Sternocleidomastoid muscle - clavicle - trapezius muscle
  - Fewer vital structures



From: <https://meducation.net/resources/30604-Triangles-of-the-Neck-Visual-mnemonic->

**2) List 6 hard and 6 soft signs of penetrating neck trauma. What are the indications for immediate OR vs CTA in managing penetrating neck trauma**

Most injuries have nonspecific signs/symptoms: serial examination is key

Box 44-2

"Soft" and "Hard" Signs of Penetrating Neck Trauma

**Soft Signs**

- Hemoptysis, hematemesis
- Oropharyngeal blood
- Dyspnea
- Dysphonia, dysphagia
- Subcutaneous or mediastinal air
- Chest tube air leak
- Nonexpanding hematoma
- Focal neurologic deficits

**Hard Signs**

- Expanding hematoma
- Severe active bleeding
- Shock not responding to fluids
- Decreased or absent radial pulse
- Vascular bruit or thrill
- Cerebral ischemia
- Airway obstruction

Presence of soft signs suggests non-vascular injury, but 5-15% may still have a vascular injury



Features of decompensation:

1. Dyspnea
2. Dysphonia
3. Stridor
4. Drooling
5. Expanding hematoma
6. Bruit
7. Cerebral ischemia
8. Shock

“HARD SIGNS” - very high likelihood of vascular injury

1. Expanding Hematoma
2. Arterial bleed
3. Roaring bruit
4. Neurologic Deficits
5. Stridor
6. Ischemia
7. No radial or weak pulse
8. Shock

Diagnostic strategies

- Key debate is whether physical exam is sensitive enough to diagnose significant injury
  - Thought to be able to identify vascular and esophageal injuries
- Use hard and soft signs as a guide

Soft signs present indicate that surgical repair is less likely needed

### **3) Describe an approach to managing acute neck trauma in the ER**

Management:

#### Stable patients

- Transport to trauma centre
  - Basic wound compression and occlusion (to prevent air embolus)
- Neurologic deficits → should prompt consideration for cervical collar

#### Unstable patients

- AIRWAY
  - #1 priority!
  - C-spine immobilization - only in the context of blunt trauma or evidence of SCI
  - RSI - is usually\*\*\* safe
  - Consider pneumothorax/hemothorax/paralysis in zone I injuries
- VASCULAR CONCERNS
  - Usually wounds with active bleeding shouldn't be probed - as it may dislodge a clot
  - AVOID blind clamping of bleeding vessels/structures!



- Trendelenburg reduces the risk of air embolism
- Place IV access on the uninjured side
- CERVICAL SPINE
  - hard collar may obscure visualization
- THORACOTOMY
  - Consider venous air embolism (to be discussed below)
    - With:
      - cardiac arrest
- NG TUBES
  - Should ideally not be placed in the awake - because the valsalva and retching may cause the patient to dislodge a clot (risk benefit decision!)

#### Disposition:

- Almost everyone gets a CT head/neck with contrast
- Based on degree of injury - often need surgery and ICU
- Anyone with platysma violation needs admission - or surgical evaluation in the ER
- Patients with blunt neck injury:
  - May have delayed signs of viscerovascular injury
- Most need to be transported to a trauma center

## 4) Describe the management of venous air embolism

Vascular trauma may lead to Venous Air Embolism (VAE):

- Anatomy:
  - Vessels of concern: carotid > subclavian > vertebral arteries, int/ext jugular veins.
- Pathology:
  - Exsanguination, expanding-compressive hematoma, direct vessel occlusion or embolization (stroke or embolism).
- Epidemiology:
  - Penetrating injuries
    - Commonly cause exsanguination
    - May have other HARD signs of vascular injury
  - Blunt injuries
    - Usually affects the carotid arteries (rarely vertebral)
    - Patients may be asymptomatic - and may present days to months later
- Pathophysiology
  - Penetrating trauma usually directly injures the structures, but the blast may also cause damage
  - Blunt trauma - can tear, thrombose, dissect, and create pseudoaneurysm formation
    - Due to neck hyperextension and hyper-rotation, intra-oral trauma, basilar skull #s, MVCs, fights, etc.
- Clinical features
  - Imaging is needed - as physical exam will miss injuries.
  - The absence of hard AND soft signs of neck trauma
  - Blunt trauma:
    - 1/2 of patients with dissections are asymptomatic



- Delayed presentation presents at TIA/Cerebral ischemia -  $\frac{1}{3}$  present after 24 hrs
  - These are some of the most under-reported injuries due to their insidious presentation and catastrophic neurologic outcome
- Horner's syndrome
  - Symptoms:
    - Carotid artery = contralateral sensory/motor deficits
    - Vertebral arteries = ataxia, emesis, visual field defects, vertigo
  - Denver and Memphis criteria may help in deciding who gets imaging, but generally older adults, anyone with hard signs, significant coma or trauma should get imaging!
  - \*\*the seat-belt signs on the neck - very few (0.8%) have a significant vascular injury\*\*
- Diagnostics:
  - CT-A may miss pseudoaneurysms, but has a 90-100% sens and specificity in penetrating trauma
    - These numbers are lower in blunt trauma - ~80% sens
  - Duplex U/S - is mediocre at identifying zone 2 injuries to the carotid, but very limited in zone 1 / 3 injuries
  - MRI-A: sensitivity is equal to CTA and worse when vertebral dissections are suspected.
  - Consider obtaining chest radiographs
- Management:
  - Penetrating injuries to the carotid - usually all get surgical repair; but some need ligation in cases of existing stroke
  - Blunt trauma:
    - Options depend on the nature of the injury:
      - 1) surgery: ligation, resection, thrombectomy, endovascular stent placement
      - 2) anticoagulation: heparin/LMWH vs. ASA
      - 3) observation
  - Venous air embolisms:
    - Can occur from blunt/iatrogenic/penetrating mechanisms
    - Results in devastating ischemic stroke - more commonly in the venous system.
- Shock, cardiac arrest; stroke-like symptoms → +/- THORACOTOMY
  - Consider venous air embolism
    - Management:
      - Direct occlusive pressure over the site!
      - Head down
      - Left lateral decubitus position (air should move to the right atrium)
      - Aspiration of air from the right ventricle using ultrasound or direct visualization!! (after thoracotomy)
  - \*\*\*\*careful when performing BVM in someone with neck trauma → this may lead to massive SC emphysema and possible air embolism



## 5) Describe techniques for airway management in penetrating neck trauma

### Airway considerations:

- Orotracheal RSI
  - Should be considered the first line technique
  - Usually successful even in neck trauma with airway distortion
  - contraindications to oro-RSI:
    - *Massive facial trauma*
    - *Laryngotracheal injury*
  - \*\*\*consider doing an awake look (+/- inline stabilization if C-spine injury) prior to paralysis
  - Important to have backup plans and anesthesia / ENT on hand if needed
- Nasotracheal intubation
  - Blind-nasotracheal intubation was once taught in ATLS → but this is no longer advertised due to risks of: bleeding, vomiting, aspiration, increased ICP, infections
  - Blind nasotracheal intubation should only be done in spontaneously breathing patients
  - Contraindicated in suspected midface or basilar skull #s or laryngeal #s.
  - McGill forceps will be helpful to help guide the tube in the right spot
- Surgical invasive airways
  - Contraindications to cricothyrotomy:
    - Large anterior neck hematoma
    - Potential laryngeal injury
  - Jet ventilation is a rescue option, with some serious downsides as well
- MISC techniques
  - Fiberoptic laryngoscopy & Bronchoscopy
    - These can be difficult with +++bleeding
  - Rescue techniques exist with:
    - LMA or King tube
- Pediatric considerations
  - Higher, more anterior, with the narrowest portion at the cricoid cartilage make airway management more difficult
  - Cricothyrotomy is contraindicated < 10 yrs of age
    - Trans-tracheal ventilation can be a salvage technique
  - oro-RSI is still the best first line choice unless it is contraindicated
- Cervical spine
  - RSI - with IN-LINE C-SPINE stabilization is safe in blunt and penetrating neck trauma
  - Indecision around airway management definitely leads to hypoxia and secondary neurologic injury
- Deciding whether to explore surgically or not to?
  - “Selective surgical management” is the mainstay of current thinking
    - Especially in a non-military setting with low velocity projectiles (handgun) and knives





- Similar mortality rates in those explored and those without exploration in zone II injuries
- Transcervical gunshot wounds
  - 2x increase in injuries that cross the midline - due to vascular damage (48%) and Cspine (24%) injuries.
  - Most prospective studies suggest that STABLE patients with TS-GSW's can have a selective surgical approach

## 6) Describe the management of suspected pharyngoesophageal trauma. What are signs of esophageal injury?

### Pharyngoesophageal trauma:

- Esophagus RARELY damaged, if so penetrating > blunt trauma. Usually the distal cervical segment
- \*\*\*important to find esophageal injuries early:
  - Spillage of orogastric contents into mediastinum = potential severe inflammation and infection
  - very often a missed injury - with a 20% mortality rate
- There are NO pathognomonic signs of esophageal injury:
  - Soft signs:
    - Hematemesis / blood in saliva/NGT
    - Odynophagia / dysphagia
    - Subcutaneous Emphysema
    - Dyspnea / hoarseness / stridor / cough
    - Pain / neck tenderness / resistance to neck movement
  - \*\*\*physical exam is unreliable\*\*\*
- Timely diagnosis is essential, a delay of 24 hrs can lead to higher mortality and morbidity
- Diagnosis depends on:
  - Imaging
    - CXR and neck x-ray are only helpful if there is pneumomediastinum or retropharyngeal air
    - Contrast-esophagography - 80--89% sensitivity
      - Using a gastrograffin study followed by barium swallow if the gastrograffin study is negative
    - Flexible endoscopy is insensitive as well
    - Combination of endoscopy and contrast swallow is - 100% sensitive
    - CT scan with contrast -
      - Has some utility in tracking the wound/bullet/knife path, but will miss some injuries - making it inadequate as a stand-alone diagnostic modality
      - CT depends on surrogate markers: paraesophageal air/fluid, esophageal edema
- Which patients to screen for injury?
  - Obtunded trauma patients
  - Those with soft signs:
    - Hematemesis, painful swallowing, sub-cutaneous emphysema
  - Very few should have a “watch and wait” approach
- Management:
  - Broad spectrum Abx - with anaerobic coverage
  - NPO
  - NGT placement under endoscopic guidance



- Uncontained perforations NEED surgery ASAP
- Contained perforations can be watched and reimaged
- Esophageal stents - are gaining popularity
- Pharyngeal injuries are watched

## 7) List 3 hard signs of laryngotracheal trauma and describe airway management dilemmas

### Laryngotracheal trauma:

- RARE! And most involve the cervical trachea
- Mechanisms:
  - MVCs - extended neck being crushed on steeringwheel
  - Clothesline injuries / poor fitting harnesses
  - Assaults / near hangings / athletic events
  - May be penetrating or blunt (think C spine injury!)
- Fractures of the cricoid cartilage can lead to DEATH due to complete airway obstruction
- Children do not have a calcified larynx - so it will not be seen on plain film:
  - The degree of airway obstruction after blunt trauma is inversely related to the degree of cartilage calcification - children are at highest risk!!
- Clinical signs:
  - Bubbling of any neck wound
  - Massive subcutaneous Air
  - Bony crepitus
  - Clothesline mechanism of injury
  - Soft signs:
    - Dysphonia / aphonia / dyspnea / stridor / hemoptysis / subcutaneous emphysema / laryngeal crepitus
    - Loss of anatomic landmarks /
    - Pain with tongue movement
    - Hoarseness
    - Tenderness over larynx
- Diagnostics:
  - Plain radiographs:
    - Looking for: extraluminal air, edema, foreign bodies, # of larynx
  - Laryngoscopy - with possible rigid laryngoscopy
  - CT scans - with 1 mm cuts and multiplanar reconstructions
    - 85-100% sensitivity - good to assess hyoid, cartilages, hematomas, crico/arytenoid joints, vocal cord integrity
    - Not as good to find mucosal perforations
    - May not be as good in pediatric uncalcified structures
- Management:
  - Delayed airway occlusion can happen at anytime - and may be rapid and life-threatening.
  - \*\*\*lots of debate regarding the best way to intubate these patients\*\*\*
  - Awake fiberoptic intubation is probably the best if available
    - There is a risk of completing a partial LT separation and creating a FALSE passage
    - \*\*don't paralyse a patient, unless you are prepared for a surgical airway\*\*
  - Consider also prepping for a tracheostomy
  - If the distal trachea has retracted into the chest - tracheal hooks are needed to recover the trachea



- LMA's are not a good rescue device given the risk for completing the LT separation
- All unstable patients need surgery
- Stable pts:
  - Analgesia, humidified air
  - Elevated HOB, antibiotics, steroids, antireflux meds,
  - Vocal rest

## Wisecracks:

### 1) Differentiate between choking, hanging and strangulation

Choking: something inside your mouth/pharynx/trachea blocking air flow

Hanging:

- a. Various terms - complete/incomplete ; typical/atypical
  - i. Based on whether or not the victim's feet were totally suspended and the location of the knot

Strangulation = may be either manual or ligature due to hands or a device compressing the neck *independent* from the weight of the patient

### 2) Define judicial and non-judicial hanging and describe expected injury patterns

Near hanging or hanging:

- Very common cause of suicide
- Pathophysiology:
  - Judicial hanging - usually distracts the head from the rest of the body due to the high fall, causing a fracture through the pedicles of C2 (hangman's), complete cord transection, and vascular disruption
  - Non-judicial hangings usually lead to venous stasis ---> congested blood flow → loss of consciousness and body relaxation
    - When the person is limp the ligature / force can tighten further leading to complete arterial occlusion and brain death
    - Vagal pressures on the carotid body may also produce fatal dysrhythmias
    - \*\*\*Vascular occlusion leads to death, rather than airway occlusion in most cases!\*\*
- Clinical features:
  - External trauma may or may not be evident
  - Marks from ligatures, hands, scratches may be present
  - Look for petechial hemorrhages: aka Tardieu's spots
    - In the conjunctiva, MM, and skin cephalad to the ligature marks
    - They occur due to rising venous pressure above the ligature
  - Laryngeal fractures, Thyroid/hyoid #'s can be present as well
  - Delayed vascular injuries are less common - but can cause carotid intimal dissection or thrombus formation
  - Consider risk for cervical fractures based on mechanism
- Management:
  - CT head and neck
  - CTA - neck



- Comatose patients need intubation and ventilation - with PEEP due to pulmonary edema or ARDS
- \*\*\*\*initial GCS is NOT predictive of outcome\*\*\*
- Prevent secondary neurologic injury

MISC other injuries not covered on the podcast:

Neurological injury:

- Be aware of the brachial plexus and peripheral nerve roots
  - Cervical sympathetic chain, cranial nerves VII, IX, X, XI and XII
  - Spinal cord
- Complete cord injury results in paraplegia, neurogenic shock, bradycardia, hypotension
- Brown sequard syndrome:
  - Ipsilateral hemiplegia and contralateral sensory changes
- Direct injury to the spinal cord - more common in GSW's but still quite rare
- Direct injury to the recurrent laryngeal nerve - causing hoarseness with paralysis of the ipsilateral vocal cord

Thoracic Duct/glandular/retropharyngeal injuries

- Thoracic duct damage presents as a chylothorax
- Endocrine gland damage - rare