

## Chapter 58 – Ankle and Foot

### Episode Overview:

- 1) Describe the bones of the foot and important joints/ligaments
- 2) List ankle stress tests
- 3) Describe an approach to ankle x rays (including the Ottawa Ankle Rules)
- 4) Describe the Weber classification
- 5) List indications for ortho referral in the ER
- 6) Describe the management of Achilles and Tibialis posterior tendon ruptures
- 7) Describe the Hawkin's classification of talar neck fractures
- 8) Describe the diagnosis and management of calcaneal fractures and list 3 injuries associated with calcaneal fractures
- 9) Describe the anatomy and classification of lisfranc injuries
- 10) Describe the management of metatarsal shaft fractures
- 11) List 6 predisposing conditions for stress fractures
- 12) List 4 causes each of hindfoot pain and forefoot pain
- 13) Differentiate between Jones and Dancer's fracture
- 14) Describe 4 plain-film radiographic abnormalities for stress fracture
- 15) Describe the Tillaux fracture and pathophysiology

### Wisecracks:

- 1) Discuss soft tissue injuries of the ankle
- 2) Name 6 other mimics of the "it's just an ankle sprain"

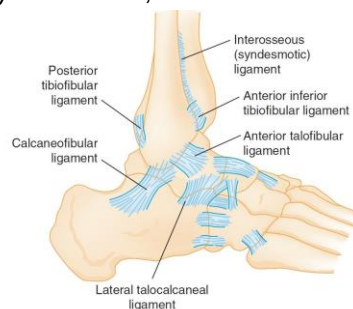
### Rosen's in Perspective

General principle is to approach ankle and foot as a single unit

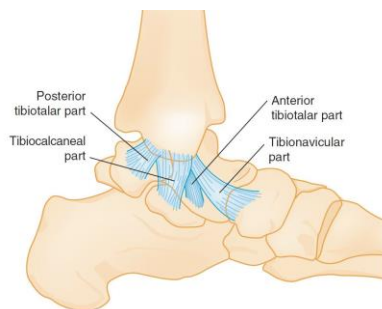
### 1) Describe the bones of the foot and important joints/ligaments

#### Ankle complex

- Ankle mortise formed by (1) medial tibia + talus; (2) tibial plafond (articular horizontal surface) + talus; (3) lateral malleolus (fibula) + talus
  - Form a contiguous joint capsule lined with cartilage called "talocrural joints"
- Tibiofibular joint also articulates
- Ankle support held by 3 ligaments
  - Syndesmotic, lateral collateral, medial collateral



**Figure 58-1.** Anatomy of the lateral collateral and the syndesmotic ligaments of the ankle. (From Nicholas JA, Hershman EB [eds]: The Lower Extremity and Spine in Sports Medicine, 2nd ed. St Louis, Mosby, 1994.)



**Figure 58-2.** Anatomy of the medial collateral ligaments of the ankle. (Adapted from Nicholas JA, Hershman EB [eds]: The Lower Extremity and Spine in Sports Medicine, 2nd ed. St Louis, Mosby, 1994.)



- Four geographic tendon groups
  - Flexor retinaculum @ medial malleolus: tibialis posterior; flexor digitorum longus; flexor hallucis
  - Peroneal retinaculum @ behind lateral malleolus: peroneus longus and brevis
  - Extensor retinaculum @ anterior ankle: tibialis anterior; extensor digitorum longus; extensor hallucis longus; peroneus tertius
  - Posterior: achilles tendon and plantaris tendon
- Motions are complex and involve the subtalar joints as well; move in x-y-z axis
- \*\*\*Stability of the ankle depends on **the RING**: >1 structure injured leads to instability

#### Clinical FEATURES:

- History: mechanism of injury; onset of pain and swelling; weight bearing ability; "pop" noise

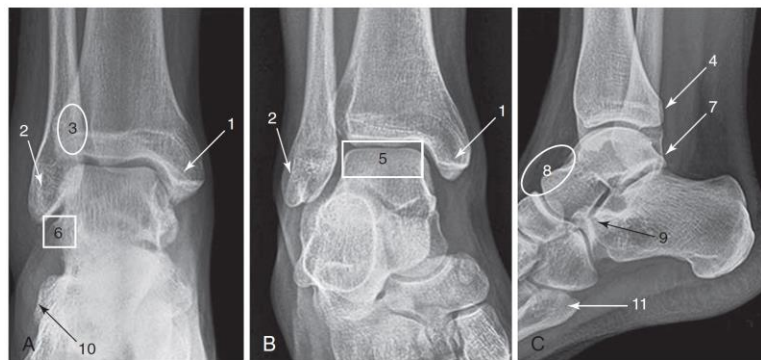
## 2) List Ankle stress tests

Physical exam: LOOK; FEEL pulses/max tenderness areas/sensation; MOVE + weight bear

- Frequently missed injuries: ?syndesmosis, fibular head #, fifth MT #, achilles tendon rupture; peroneal tendon rupture
- Stress tests:
  - Of questionable significance in the ER
    - Potential utility in a distal fibular fracture with deltoid complex pain
  - **Anterior drawer test**
    - Assesses the ATFL
    - Seated with knee at 90 deg. and a neutral ankle
    - Cup the heel with your palm while passively flexing the hip and assess for talar displacement
    - +ve if:
      - "Clunk" noticed
      - Sulcus appears antero-medially over the joint
  - **Inversion stress test**
    - Aka. Talar tilt test
    - Assesses the ATFL and CFL
    - Invert heel while knee is flexed at 90 degrees and ankle in neutral position
    - +ve if:
      - Head of talus palpated laterally
      - Increased laxity compared to the other side
  - **External rotation stress test**
    - Used to assess the tibiofibular syndesmosis
    - Externally rotate the foot (knee at 90, ankle neutral)
      - +ve with:
        - Pain at the syndesmosis
        - Sensation of lateral talar motion
  - **Syndesmosis stress tests**
    - Cross-leg test
    - Mid-calf squeeze test


### 3) Describe an approach to ankle x rays (including the Ottawa ankle rules)

- Radiology: 3 views is standard
  - Plain radiographs miss:
    - Subtle fractures, osteochondral lesions, stress fractures, ligament injuries
      - Bone scan is useful for stress fractures, syndesmosis injury or osteochondral lesions
      - CT scan: stress fractures and ligament injuries
      - MRI: ligament and tendon anatomy and subtle bone marrow changes seen in stress fractures before seen on x ray
      - CT-SPECT imaging: impingement syndromes, tumors, osteomyelitis
  - Look at at least 11 spots including "tear drop" sign of joint effusion and ensure **NO more than 4 mm** in the medial clear space:



**Figure 58-5.** Approach to reviewing ankle radiographs. A to C, A standard radiographic series of the ankle has three views: an anteroposterior view (A), an internal rotation or mortise view (B), and a lateral view (C). The following 11 locations should be carefully scrutinized, as they are areas where fractures frequently occur: the medial (1) and lateral (2) malleoli, anterior tibial tubercle (3) and posterior tibial malleolus (4), talar dome (5), lateral talar process (6), tubercles of the posterior talus process (7), dorsal to the talonavicular joint (8), anterior calcaneus process (9), calcaneal insertion of the extensor digitorum brevis (10), and the base of the fifth metatarsal bone (11). (From Yu JS, Cody ME: A template approach for detecting fractures in adults sustaining low-energy ankle trauma. Emerg Radiol 16:309, 2009.)

- Ottawa ankle and foot rules, 100% sensitive



## Ottawa Ankle Rules

For Ankle Injury Radiography

**MD+  
CALC**

An **ankle** x-ray series is only required if there is any pain in the malleolar zone and any of these findings:

- 1) Bone tenderness at A
- OR
- 2) Bone tenderness at B
- OR
- 3) Inability to bear weight both immediately and in the ED

A **foot** x-ray series is only required if there is any pain in the midfoot zone and any of these findings:

- 1) Bone tenderness at C
- OR
- 2) Bone Tenderness at D
- OR
- 3) Inability to bear weight both immediately and in the ED

© Ottawa Health Research Institute

See: <http://www.mdcalc.com/ottawa-ankle-rule/>

- Weight bearing defined as the ability to transfer weight onto each leg *regardless of limping* at least 4 steps
- Not applicable in subacute and chronic injuries
- Validated in kids >5 yrs old
- Do NOT apply to hind or fore foot injuries.
- Not reliable in patients with:
  - Intoxication
  - Distracting injuries
  - Gross swelling that prevents palpation of bony tenderness
  - Peripheral nerve damage (e.g. diabetic neuropathy in the feet)
- Syndesmosis evaluation:

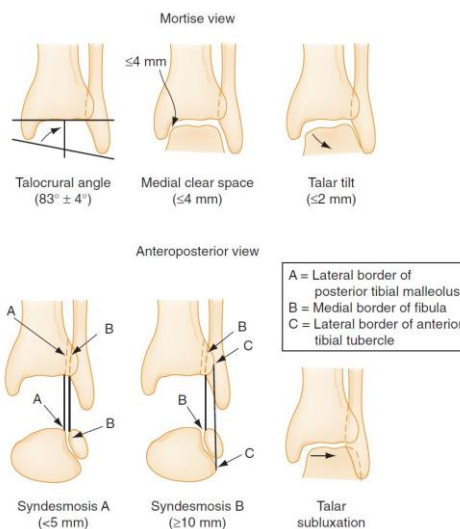


Figure 58-6. Radiologic criteria for evaluating the syndesmosis. (From Stiehl JB: Ankle fractures with diasthesis. Instr Course Lect 39(III):79, 1990.)

#### 4) Describe the Weber classification

##### ANKLE FRACTURES:

- LOOK on the opposite side of the ligament injury for the fracture.
- Classification
  - Danis-Weber system
- Management
  - Immediate reduction of a fracture dislocation
  - Immobilize, elevate, ice

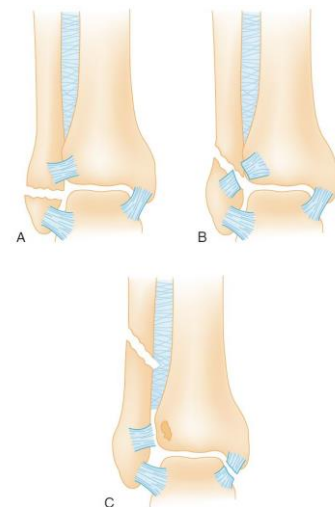


Figure 58-8. The Danis-Weber classification of ankle fractures focuses on the location of the fibular fracture in relation to the tibiotalar joint and syndesmosis. See text for explanation. (From Wilson FC: The pathogenesis and treatment of ankle fractures: Classification. Instr Course Lect 39(III):79, 1990.)

##### Specific ankle Fractures:

- Unimalleolar fractures
  - Lateral Malleolar Fractures
    - Weber A: cast, non-weight bearing (NWB) x 3 weeks, ortho f/u
      - Ensure no deltoid ligament pain
    - Weber B & C: need ortho referral asap



- Plain x-ray measurements only 31% sensitive to detect syndesmosis injuries
- Medial Malleolar fractures (eversion or external rotation injuries)
  - \*\*Must rule out fibular fracture\*\*
  - Ortho referral ASAP, cast, NWB x 3 weeks
- Posterior Malleolar Fracture
  - Rare
- **Bimalleolar** fractures: \*unstable
  - Caused by an oblique shearing force
  - May still be non-operative if stable.
  - May need a CT scan to figure the subtle #'s
- **Trimalleolar** fractures: Medial, lateral AND posterior malleoli
  - All need ORIF
- **Open** fractures:
  - Irrigation, reduction
  - ABx, tetanus
    - Ancef, Gentamycin
    - Add Clindamycin or Penicillin G for soil contamination (for Clostridium)
- **Pilon** fractures
  - Distal tibial metaphysis (falls)
  - Look for calcaneus, tibial plateau, femoral neck, acetabulum, lumbar vertebrae injuries
  - Catastrophic recoveries and post-injury arthritis

## 5) List indications for orthopedic referral in the ER

- Disposition: Refer for these fractures

Box 58-1	Ankle Fractures for Which Orthopedic Consultation in the Emergency Department Is Recommended
	Unimalleolar fractures Displaced medial malleolar fracture Medial malleolar fracture with lateral collateral ligament rupture Displaced lateral malleolar fracture Lateral malleolar fracture with deltoid ligament rupture Lateral malleolar fracture with widened medial clear space Unimalleolar fracture with syndesmotic diastasis Fibula fracture at or proximal to the tibiotalar joint line Displaced posterior malleolar fracture Posterior malleolar fracture involving more than 25% of articular surface All bimalleolar fractures All trimalleolar fractures All intra-articular fractures with step deformity All open fractures All pilon fractures

- Any displaced unimalleolar fractures
  - Especially with comorbid contralateral ligament disruption (syndesmosis, deltoid, lateral collateral ligaments)
  - OR abnormal mortise measurements
  - And intra-articular fracture that exceeds the rule of 3: > 3mm diameter, >1/3 the articular surface
- ALL
  - Bimalleolar, Trimalleolar, intra-articular, OPEN, Pilon #'s





## 6) Describe the management of Achilles and Tibialis posterior tendon ruptures

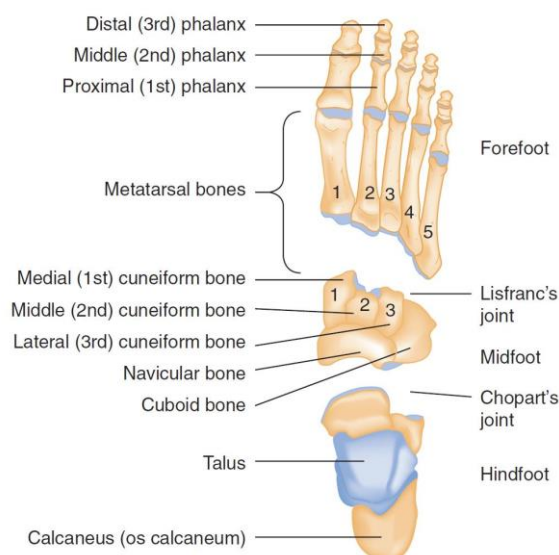
- Tendon injuries
  - Achilles Rupture: "the middle-aged man"
    - Risk factors:
      - Forced dorsiflexion; rheumatoid arthritis; SLE; gout; hyperparathyroidism; CRF; steroid use; fluoroquinolone; previous rupture
    - "Loud pop", weakness with plantar flexion (action compensated by tibialis posterior, toe flexors and peroneal muscles)
    - Up to 25% of cases are missed!!!
    - Thompson test: prone patient with knee flexed/kneeling on chair, squeeze the calf
    - Silfverskiöld test: compares dorsiflexion bilaterally (greater on injured side)
    - Get a lateral radiograph to rule out bony avulsion or tendon calcification
    - MGMT: based on ortho on call
      - Operative for young healthy athletes or re-rupture
        - In Victoria:
          - 48 hrs since injury → FB cast in plantar flexion x 6 weeks, then graduated walking boot with heel lifts
          - >48 hrs since injury → consider OR
      - Non-operative otherwise
  - Peroneal tendon dislocation or tear\*\*
    - Function as everters and pronators of the foot
    - Peroneus longus and brevis reside in the fibular groove @ posterior lateral malleolus as a pulley for the midfoot insertion
      - **Brevis** inserts on the fifth. MT tuberosity
      - **Longus** inserts on medial cuneiform + base of 1st MT
    - Superior peroneal retinaculum holds the peroneal tendons in place: \*tear of the retinaculum may need surgery
      - Hx: "snapping" sensation, weakness with eversion
      - Px: no eversion while foot dorsiflexed
    - MGMT: need radiography, and dislocations need surgical trxt
  - Tibialis posterior tendon rupture:
    - Plantar flexes and inverts the ankle: pulley is located at the post-inferior surface of medial mall. and inserts on the midfoot
    - Balanced by the peroneus brevis
    - Hx: "forced" eversion
    - Px: unable to toe raise, see more "toes"
    - \*May\* need surgery and ortho f/u

- *Other tendon injuries:*
  - Tenosynovitis of tibialis anterior
  - Rupture of Tibialis anterior is rare
  - Flexor hallucis longus tendinitis "dancer's tendinitis"
- *Ankle dislocations:*
  - May go in any direction and be open or closed
  - \*\*Neurovascular assessment and rapid reduction!!\*
  - Must flex knee to 90. degrees, and distract to reverse the injury

## FOOT

- **Principles of disease**

- **Anatomy:**



**Figure 58-14.** Bones and joints of the foot. (From Rockwood CA, et al [eds]: Rockwood and Green's Fractures in Adults, 3rd ed. New York, JB Lippincott, 1991.)

- The extrinsic muscles of the foot maintain the arch and beam structure of the foot
  - Nerves: deep and superficial peroneal nerves, post. tibial, saphenous and sural nerves
  - Inversion and eversion of hind foot occur through the subtalar joint
  - Adduction and abduction occur through the midfoot
- **Clinical features:**
  - \*\*Mechanism of injury\*\*
  - Standard approach to Hx and Px with MSK injuries
- **Diagnostic imaging:**
  - 3 views
  - Special views: weight bearing, axial view
  - Beware of accessory bones: smooth corticated surfaces may be present anywhere in the foot!
  - Sesamoids exist by the 1st and 2nd metatarsals.
  - MRI better than bone scans for finding stress fractures

- CT scan: great for forefoot and hindfoot

## Specific pathologic conditions

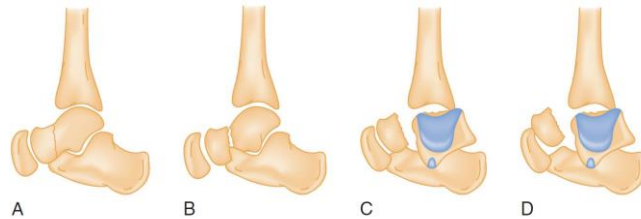
### 7) Describe the Hawkin's classification of talar neck fractures

- **Hindfoot injuries:**

- Talar #:
  - Has 7 articulations: bears an immense amount of weight
  - No muscular attachments holding it in place
  - More prone to dislocate when the foot is plantar flexed
  - Has tenuous blood supply: #'s at high risk for AVN
  - Subtle fractures can be missed, e.g. lateral process fractures in snowboarders
  - 50% talar #'s are at the neck due to forced dorsiflexion

- Classified using the Hawkins system 1-3

#### **Talar neck fractures:**



**Figure 58-16.** A, B, and C, Hawkins's type 1, 2, and 3 fractures, respectively. D, Canale and Kelly's type 4 fracture of the talar neck. Purple shading indicates the articular surface of the talar dome. (From Gustilo RB, et al [eds]: Fractures and Dislocations. St Louis, Mosby, 1993.)

- Type 1: Non-displaced
- Type 2: Subtalar subluxation
- Type 3: 50% are open #, dislocation of the talar body from ankle and subtalar joint
- Type 4: Type 3, with distraction of the talonavicular joint
- The higher the type, the higher the risk of AVN and arthritis
- Found by painful inversion/eversion
- Dx:
  - X-ray: very poor at finding these #'s
  - CT/MRI
- Tx: generally need operative fixation, unless minor, in which they are NWB >8 wks
- High incidence of complications post ORIF
- **Osteochondral lesions: "persistent ankle pain after a sprain"**
  - Injuries involving the articular surface (cartilage) / subchondral region (bone)
  - Commonly occur with ankle sprains: gross edema + effusion --> Chronic ankle pain
  - Dx: with MRI, showing bone marrow edema and cartilage injury
  - Tx: prolonged immobilizations or operative mgmt.



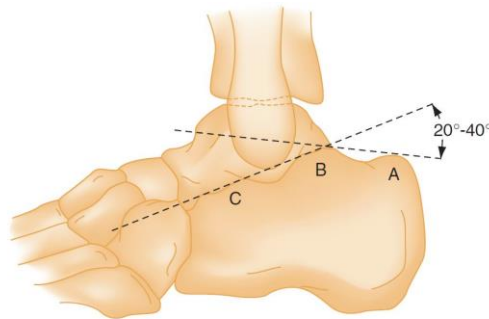
- **Subtalar / total talar dislocation:**

- Severe torsional forces in MVC's or falls.
- Disrupt talo-calcaneal-navicular ligaments
- May be missed despite an abnormal appearing foot on the AP radiograph
- Mgmt: need prompt reduction under anesthesia:
  - May need operative intervention due to buttonholing of nearby anatomy

## 8) Describe the diagnosis and management of calcaneal fractures and list 3 injuries associated with calcaneal fractures

- **Calcaneal fractures:**

- Either extra/intra-articular
- Usually result of a fall on the heels.
- Plain radiography:
  - Key questions: ?does it involve the subtalar joint; ?does it depress the posterior facet
  - Bohler's angle: may be normal in a severely comminuted fracture



**Figure 58-22.** Bohler's angle is obtained by measuring the angle formed by two lines, one between the posterior tuberosity (A) and the apex of the posterior facet (B) and the other between the apex of the posterior facet (B) and the apex of the anterior process (C). A value less than 20 degrees suggests a calcaneal compression fracture. (From Rosen P, et al [eds]: Diagnostic Radiology in Emergency Medicine. St. Louis, Mosby, 1992.)

- On the lateral view: <20 degrees=compression fracture
- CT scan: much better!
- Mgmt:
  - Debate on non-displaced fracture mgmt: OR or not
  - Extra articular fractures if non-displaced may be managed by cast for 6-8 weeks
  - HIGH incidence of long term pain and disability

## 9) Describe the anatomy and classification of lisfranc injuries

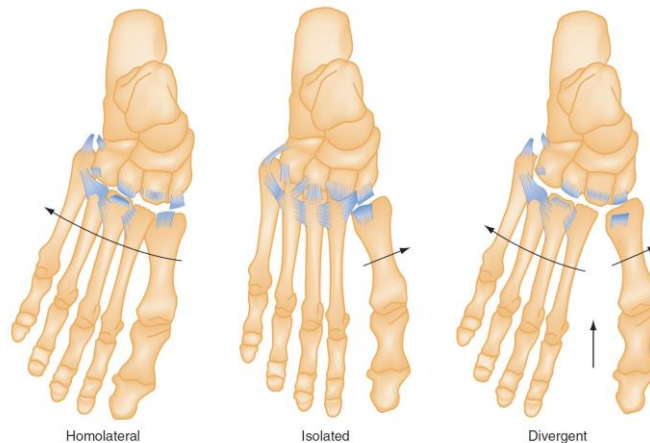
- **Midtarsal joint injuries: rare**

- **Midfoot injuries**

- **Navicular "ship"**

- High risk for AVN: analogous to the scaphoid
- #1 midfoot fracture

- Dx: on pain or palpatory tenderness over the bone
- Common accessory navicular bone may be confused for a #
- Outpatient ortho f/u
- **Cuboid #'s**
  - Commonly associated with a Lisfranc injury
  - Peroneus longus tendon inserts on this bone and may complicate #'s
- Cuneiform fractures:
  - Look for the Lisfranc!!
- **Lisfranc fractures - Tarsometatarsal #'s**
- ANY injury to this joint is a Lisfranc injury
  - Multiple anatomic structures give this area the cornerstone stability of the foot
  - Mech of injury: rotation on a fixed forefoot (equestrian, windsurfing); axial loads (MVC); crush injuries; trivial stumbles and falls.
  - Classification



**Figure 58-23.** Classification of Lisfranc injuries. The ligamentous anatomy of the Lisfranc complex also is depicted. (From Hardcastle PH, et al: Injuries to the tarsometatarsal joint: Incidence, classification and treatment. J Bone Joint Surg Br 64:349, 1982.)

- There is often a DORSAL displacement component seen on the lateral view
- Look for fractures of the 2<sup>nd</sup> metatarsal base
- \*\*A critical branch of the dorsalis pedis artery divides between the 1<sup>st</sup> and 2<sup>nd</sup> MT\*\*
- **Clinical features:**
  - Up to 20% are missed
  - Midfoot pain, unable to weight bear
- **Diagnostic strategies:**
  - Subtle findings on X-ray
    - Clue of proper alignment on AP and lateral views:
      - MT's 1-4 each line up with the medial edges of their tarsal articulations
      - \*\*Medial edge of the base of the 2nd MT lines up with the medial edge of the middle cuneiform\*\*
      - Any # around Lisfranc joint = LF injury\*\*\*



- STRESS views aid in the Dx. of the #
  - Comparison views if needed
- CT - best test; MRI for assessing joint complex instability
- **Management and disposition**
  - Closed reduction and internal fixation with K wires
  - Non weight bearing cast for 12 weeks, with an orthotic for 1 yr.
  - A LF sprain may just need immobilization for 6 weeks
  - Complications:
    - arthritis, compartment syndrome, pain, loss of arch, CRPS

## 10) Describe the management of metatarsal shaft fractures

### Forefoot injuries:

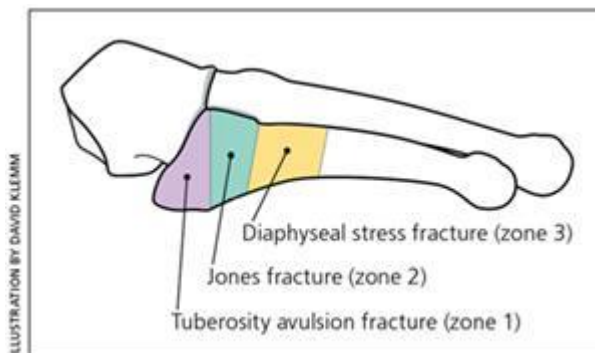
#### Metatarsal #'s

- Classified: base, shaft, head, neck
- **MT shaft #**
  - Based on mechanism of injury
  - First MT injuries require more aggressive care because it carries twice the load
  - Displaced fractures can lead to problems with the foot arch and neuromas and need correction!
  - Undisplaced 2nd-5th MT #: all heal well
    - Treatment = below knee walking cast 2-4 weeks vs. non wt. bearing cast 4-6 weeks vs. stiff shoes and a metatarsal pad
  - Great toe MT: aggressive mgmt
    - Non-displaced: at least the first 3 weeks of non-wt. bearing
    - Displaced:
      - Reduction if >3mm displacement or >10 deg. angulation
      - May need ORIF or simply closed reduction
  - Any displaced 1st or 5th MT fracture generally need surgery
  - Watch for Compartment syndrome!
  - Non-wt bearing unnecessarily often leads to complex regional pain syndrome...so encourage appropriate wt. bearing
  - Disposition:
    - Know when to refer:
      - displaced #'s
      - multiple #'s
      - 1st or 5th MT #'s
- **MT head and neck #'s**
  - Displaced fractures need precise re-alignment
- **MT base #:s**
  - Beware of accessory ossicles of the foot!

- 1-4th MT beware of the Lisfranc injury
- 5th MT =
  - Tuberosity or fifth metatarsal STYLOID fracture
    - Due to a suddenly inversion of a plantar flexed foot
    - Managed with a walking cast for 2-3 weeks if not displaced and not intra-articular
  - BASE of 5th MT: "jones" fracture or **diaphyseal** fracture
    - Running and jumping injury
    - >15 mm from the proximal end of the bone
    - Stress fractures need prolonged mgmt. and may need operative management
    - Usually have delayed union/nonunion/and prolonged healing times

For a discussion of the different types:

<http://www.wikiradiography.net/page/Fifth+Metatarsal+Fractures>



- **Management**
  - If intra-articular and >25-30% of the joint involved needs a K-wire and non wt, bearing for 6-8 weeks
- **Phalangeal fractures:**
  - Very common, especially proximal phalanx of the fifth toe
  - If possible position the uninjured toes out of the way
  - Evacuate subungual hematomas
  - **Management:**
    - Non displaced: buddy tape with gauze or padding between toes
    - Displaced: reduce, may need OR if profound rotatory deformity
    - HALLUX fractures: buddy taped with a walking boot x 2-3 weeks.
      - Need OR if largely intra articular or displaced
- **Sesamoid fractures**
  - Some people have a bipartite sesamoid
  - Treatment: below knee walking cast for 3-4 weeks, Non-operative
- **MTP dislocations**
  - Watch for sesamoid fractures or displacements
  - Treatment
    - Longitudinal traction



- Walking cast and toe plate x 3 weeks for 1st MTP dislocations
- Common sense for the rest of them

## 11) List 6 predisposing conditions for stress fractures

- **Stress fractures:**

- Most due to running:
  - Risk factors: new footwear, change in running surface, overuse/overtraining, female athlete triad/**relative energy deficit syndrome**, steroid use, vitamin / mineral deficiency, cavus feet
- 2nd and 3rd MT shafts most common
- Calcaneal stress # common
- Localized insidious pain
- Plain x rays normal upto 4-6 weeks!
- Bone scans: decent; MRI is imaging of choice for stress fractures
- Treatment
  - 4-6 weeks of limited activity
  - Navicular stress fractures & chronic diaphyseal stress #s: \*\*non wt. bearing for 6-8 weeks\*\*
    - Some may need up to 20 weeks of casting!

## 12) List 4 causes each of hindfoot pain and forefoot pain

- **Foot pain:**

- Three things to think about:
  - Complex regional pain syndrome
    - Occurs months after trauma
    - Diffuse burning, aching, searing
    - Vasomotor instability
  - Persistent foreign body
  - Stress fractures
- Break it down into
  - Hindfoot pain
    - Stress fractures of talus or calcaneus
    - Impingement by os trigonum: pain during plantar flexion of the foot in ballet dancers
    - Subcalcaneal foot pain:
      - Plantar fasciitis:
        - Overuse injury
        - Pain during gait
        - Calcaneal spur on plain xray
        - Treatment:
          - Rest, padding, orthotics, NSAIDs
      - Subcalcaneal bursitis
      - Rupture of plantar fascia
      - Nerve compression
        - Tarsal tunnel syndrome
  - Midfoot pain
    - Stress fracture of navicular bone



- Symptomatic accessory ossicle
  - Bone scan with surgical excision
- Forefoot pain
  - Bunions
  - Blisters
  - Corns/callouses
  - Hammertoes
  - Ingrown toenails
  - Metatarsalgia: stress fractures or neuromas
  - Morton's neuroma

### 13) Differentiate between Jones and Dancer's fracture

- **Jones #**
  - Does not involve the cubometatarsal articulation (doesn't extend proximally from the 4-5th metatarsal articulation)
  - Is not a tuberosity/avulsion fracture
  - Occurs at the meta-diaphyseal region - in the absence of ankle inversion
    - Zone II
    - Area of poor vascularity, high risk of non-union
- **Dancer's #**
  - Zone III injuries, in the diaphyseal region
  - "Metatarsal base fractures typically occur in the cancellous region of the MT base, and likely occur due to an inversion strain of the lateral plantar aponeurosis. Metatarsal base fractures, when minimally displaced, heal well treated non-operatively."
  - Copied from: <http://www.aofas.org/PRC/conditions/Pages/Conditions/Fifth-Metatarsal-Fractures.aspx>

### 14) Describe 4 plain-film radiographic abnormalities for stress fracture

"Plain radiographs have poor sensitivity in detecting stress fractures, as positive findings may take months to appear. During the first few weeks after the onset of symptoms, x-rays of the affected area may look normal.

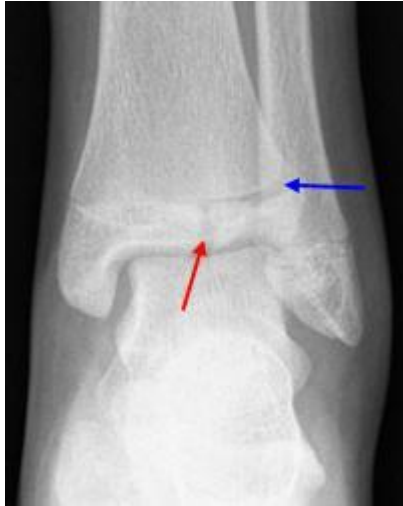Positive findings include:

1. Sclerosis,
2. Periosteal reaction/elevation,
3. Cortical thickening
4. Fracture line."

Copied from: <https://radiopaedia.org/articles/stress-fractures>



## 15) Describe the Tillaux fracture and pathophysiology



From: <http://orthoinfo.aaos.org/topic.cfm?topic=A00632>

- **Tillaux fractures** are Salter-Harris III fractures through the anterolateral aspect of the distal tibial epiphysis, with variable amounts of displacement
- Pathophysiology: occurs because the epiphyseal plate closes in a medial→lateral fashion
- Occurs in an abduction-external rotation mechanism, requires an open epiphysis. Kids usually 12-15 yrs old.
- May require ORIF depending on degree of displacement

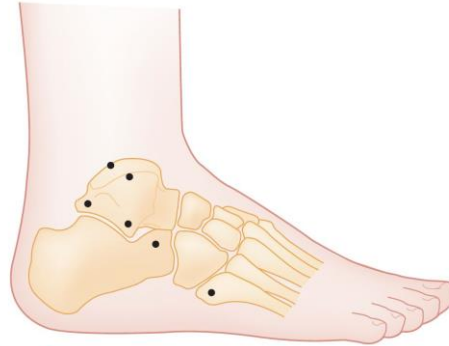## Wisecracks:

### 1. Discuss soft tissue injuries of the ankle

Soft tissue injuries:

- Ligament injuries:
  - AntTFL > CalcFL > > PostTFL
  - Grade I: stretching without tearing or joint instability
  - Grade II: partial tear, SWELLING PAIN, and mod. instability
  - Grade III: complete tear, severe edema and ecchymosis.
  - Inability to wt. bear = grade 2/3 injury if no #
  - **\*\*Must exclude deltoid ligament or syndesmosis injury\*\***
  - Ligament stress testing is moderately useful, and should be compared bilaterally
    - Anterior drawer/talar tilt/external rotation test: lateral ligament injuries
  - Look for AVULSION fracture
- Syndesmosis measurements (there are two places to measure)
  - Normal (no diastasis)
    - 1) "bony gap" under 5 mm

- <5mm between lateral border of post. tib. malleolus and medial border of fibula
- 2) "bony overlap" over 10 mm
  - >=10 mm of overlap between medial border of fibula and lateral border of ant. tibial tubercle.
- DDx of "presumed ankle sprain"



**Figure 58-12.** Locations of common fractures in or near the ankle that should be considered in the differential diagnosis of a presumed ankle sprain. (From Gustilo RB, et al [eds]: Fractures and Dislocations. St Louis, Mosby, 1993.)

- Don't miss the nearby fractures or subtle peroneal tendon injury!!
- Management of ankle ligament injuries:
  - \*almost NO benefit of surgery\*
  - Functional treatment is the mainstay and lasts 4-6 weeks
    - Allows for partial joint function:
      - Phase 1:
        - RICE
        - lace up ankle support is more effective in long term edema reduction and improved functioning
        - Grade 1-2 strains can get help from tensors
        - Very severe grade 3 sprains may help from 10 days of walking boot +/- crutches until walking is pain-free
        - Pain mgmt: NSAIDS, acetaminophen, topical diclofenac gel
      - Phase 2-3:
        - Wt bearing (with no pain)
        - Exercises and proprioceptive, etc.
  - Disposition:
    - Refer: non-healing primarily managed ankles; fibula avulsions>3mm
    - Long term functional/mechanical instability; chronic pain; stiffness, and recurrent swelling or popping need f/u and imaging



- **Contusions & sprains:**
  - Achilles tendon and posterior tibial tendons = #1 ruptures
  - Extensor and flexor hallucis longus tendons need primary repair
- **Compartment syndrome:**
  - "An increase in pressure in an osseofascial space that impedes neurovascular function resulting in tissue damage"
  - At least 4 foot compartments as well as pedal compartment syndrome
  - **Clinical features:**
    - Pain out of proportion
    - Intense burning pain
    - Pain exacerbated by ANY active or passive movement
    - Pulses and capillary refill are often **NORMAL!!!**
  - Dx:
    - Pressures >30
  - Mgmt:
    - Position limb at the level of the heart
    - Ortho referral!

## 2. Name 6 other mimics of the “it’s just an ankle sprain”

### Box 58-2 Differential Diagnosis for Presumed Ankle Sprain

Lateral collateral ligament sprain  
Peroneal tendon dislocation  
Osteochondral lesion of the talar dome  
Fracture of the posterior process of the talus  
Fracture of the lateral process of the talus  
Fracture of the anterior process of the calcaneus  
Midtarsal joint injury  
Fracture of the base of the fifth metatarsal